THE PLANET

Original Article

Clinical and Functional Outcomes Following PHILOS Plate Fixation of Proximal Humerus Fractures: An Assessment of Fracture Union, Implant-Related Complications, and Functional Outcome Categories

S Ripon Kumar Ghosh[1*], Shahidul Islam[2], Nripen Kumar kundu[3], Prianka Ghosh[4], Milton Morshed[5], Saikat Ghosh[6]

ARTICLE INFO

Received: 6 November 2026
Accepted: 16 November 2026
Published Online: 19 November 2026

DOI: 10.5281/zenodo.24356343

Volume: 10, Number: 3, Page: 1312-1317

e-ISSN: 2789-5912
ISSN: 2617-0817

*Corresponding author

ABSTRACT

Background: Proximal humerus fractures are common injuries that can substantially impair shoulder mobility and functional independence. Proximal Humeral Internal Locking System (PHILOS) plate fixation provides angular stability for selected displaced fractures; however, fracture healing, implant-related complications, and postoperative functional recovery remain important indicators of treatment outcomes. **Aim of the study:** To assess clinical and functional outcomes following PHILOS plate fixation of proximal humerus fractures, with particular emphasis on fracture union, radiological alignment, implant-related complications, functional outcome categories, and factors associated with final functional recovery. **Methods & Materials:** This observational analytical study included 84 patients who underwent PHILOS plate fixation at the Department of Orthopaedics, [Institution name], Bangladesh. Sociodemographic, clinical, fracture-related, operative, and postoperative data were collected from patient interviews, clinical examinations, operative records, radiographs, and follow-up assessments. Fracture union, final radiological alignment, and postoperative complications were evaluated during follow-up for up to 12 months. Functional recovery was assessed using the Constant–Murley Score at 6 weeks and 3, 6, and 12 months. Final functional outcomes were categorized as excellent, good, fair, or poor. Associations between clinical factors and favorable or unfavorable functional outcomes were analyzed using the chi-square test or Fisher's exact test, as appropriate. A p-value of less than 0.05 was considered statistically significant. **Result:** Three-part fractures were the most common fracture pattern, accounting for 42.86% of cases, followed by two-part fractures (34.52%) and four-part fractures (22.62%). Radiological union without delayed union was achieved in 89.29% of patients, and acceptable final alignment was observed in 90.48%. At 12 months, the mean Constant–Murley Score increased to 75.20 ± 12.10 from 46.80 ± 9.70 at 6 weeks. Excellent, good, fair, and poor functional outcomes were observed in 16.67%, 38.10%, 27.38%, and 17.86% of patients, respectively. At least one postoperative complication occurred in 23.81% of patients, with shoulder stiffness being the most frequent complication (11.90%); 7.14% required reoperation. Union status (p=0.039) and complication status (p=0.043) were significantly associated with final functional outcomes, whereas age (p=0.123) and fracture pattern (p=0.215) were not. **Conclusion:** PHILOS plate fixation was associated with satisfactory fracture union, acceptable radiological alignment, and progressive functional improvement over 12 months. Delayed union or nonunion and postoperative complications were significantly associated with unfavorable functional outcomes. Careful surgical technique, appropriate postoperative monitoring, complication prevention, and structured rehabilitation may contribute to better functional recovery following fixation of proximal humerus fractures.

Keywords: *Proximal humerus fracture; PHILOS plate fixation; fracture union; implant-related complications; Constant–Murley Score.*

1. *Assistant Professor, Department of Orthopedic & Spine Surgery, Ad-Din Women's Medical College Hospital, Dhaka, Bangladesh (ORCID: 0009-0002-3326-8217)*
2. *Professor and Head, Department of Orthopedics & Spine, Ad-Din Medical College Hospital, Dhaka, Bangladesh*
3. *Associate professor, Department of Orthopaedic, Popular Medical college and Hospital. Dhanmondi, Dhaka, Bangladesh*
4. *Medical Officer, Barak PRP Medical Centre & General Hospital, Dhaka, Bangladesh*
5. *Assistant Professor (C.C.), Department of Orthopaedic Surgery, Gonoshathaya Samajvittik Medical College, Savar, Dhaka, Bangladesh*
6. *Junior consultant, UHC, Kutubdia, Coxsbazar, Bangladesh*

INTRODUCTION

Proximal humerus fractures are common injuries of the shoulder joint that can significantly impair upper-limb function, particularly in older adults and individuals involved in road traffic accidents or falls [1]. These fractures account for approximately 5–6% of all adult fractures, with their incidence increasing with age due to osteoporosis and reduced bone strength [2]. The proximal humerus plays a crucial role in shoulder mobility and stability; therefore, fractures involving this region can substantially affect daily activities, independence, and quality of life [3]. The clinical presentation and prognosis vary according to fracture displacement, comminution, bone quality, and involvement of the articular surface. Appropriate treatment is essential to achieve fracture healing, restore shoulder function, and minimize complications [4]. The management of proximal humerus fractures depends on fracture configuration, displacement, patient age, functional requirements, bone quality, and associated injuries [1]. While conservative treatment is appropriate for many minimally displaced fractures, displaced, unstable, and complex fractures may require surgical intervention [5]. Available surgical options include percutaneous pinning, intramedullary nailing, conventional plate fixation, and shoulder arthroplasty [1]. Among these approaches, open reduction and internal fixation using a proximal humeral internal locking system (PHILOS) plate has gained considerable attention because of its angular stability and suitability for fractures involving osteoporotic bone [6]. The locking screw mechanism provides stable fixation and helps maintain fracture reduction, while the anatomically contoured plate facilitates fixation of the proximal humerus with minimal additional implant contouring [7]. PHILOS plate fixation is particularly useful for selected two-part, three-part, and four-part proximal humerus fractures where preservation of the native humeral head is feasible [8]. The technique aims to restore anatomical alignment, maintain fracture stability, and permit early postoperative mobilization. Early rehabilitation may help reduce shoulder stiffness and improve functional recovery [9]. However, satisfactory outcomes depend on appropriate patient selection, accurate

BDJOURNALS.ORG Copyright © 2026 The Planet. Published by Sher-E-Bangla Medical College, Barishal, Bangladesh. This is an open access article under the CC BY license (http://creativecommons.org/licenses/by/4.0/).

fracture reduction, correct implant positioning, secure fixation, and adherence to postoperative rehabilitation protocols [10]. Despite these advantages, PHILOS plate fixation is associated with potential complications, including screw penetration into the joint, varus collapse, loss of reduction, subacromial impingement, avascular necrosis of the humeral head, infection, and delayed union or nonunion. These complications may adversely affect fracture healing and limit postoperative shoulder function [11]. Fracture union and functional recovery are important indicators for evaluating the success of PHILOS plate fixation. Radiological assessment helps determine whether satisfactory bone healing has occurred, whereas clinical and functional evaluations provide information regarding pain, shoulder mobility, strength, and the ability to perform routine activities [12]. Although PHILOS plating is widely used for proximal humerus fractures, postoperative outcomes may vary according to fracture characteristics, patient-related factors, surgical technique, and rehabilitation practices. Local evidence evaluating fracture union, implant-related complications, and functional outcome categories together remains important for improving clinical decision-making and postoperative care. Therefore, this study aimed to assess the clinical and functional outcomes following PHILOS plate fixation of proximal humerus fractures, with particular emphasis on fracture union, implant-related complications, and the distribution of functional outcome categories.

METHODS & MATERIALS

This observational analytical study was conducted among 84 patients undergoing proximal humerus fracture fixation using a Proximal Humeral Internal Locking System (PHILOS) plate conducted at the Department of Orthopedic & Spine Surgery Ad-Din women's Medical College Hospital, Barak PRP Medical Centre & General Hospital and Some Private Hospitals, Dhaka, Bangladesh from July 2024 to June 2026. The study aimed to assess fracture union, radiological outcomes, implant-related complications, functional recovery, and factors associated with final functional outcomes following PHILOS plate fixation. Patients were selected using a purposive sampling technique. Clinical, operative, radiological, and functional outcomes were assessed during follow-up for up to 12 months after surgery.

Inclusion Criteria

- Patients aged 18 years or older with a proximal humerus fracture.
- Patients treated surgically with PHILOS plate fixation.
- Patients with fractures classified according to the Neer classification.
- Patients with available preoperative, operative, and postoperative clinical and radiological records.
- Patients who attended the scheduled follow-up assessments and had functional outcome data available.
- Patients who provided informed consent for participation and follow-up, where applicable.

Exclusion Criteria

- Patients younger than 18 years.
- Patients with pathological fractures or fractures associated with bone tumours.
- Patients managed conservatively or treated using fixation methods other than a PHILOS plate.
- Patients with open fractures or associated injuries that substantially affected shoulder function, if excluded according to the study protocol.
- Patients with incomplete clinical, radiological, or functional outcome records.
- Patients who were lost to follow-up before assessment of the relevant outcomes.

Data Collection

Data were collected using a structured data collection form from patient interviews, clinical examinations, operative records, radiographs, and follow-up assessments. Sociodemographic and clinical variables included age, gender, affected side, mechanism of injury, diabetes mellitus, hypertension, and other documented comorbidities. Fracture-related variables included Neer classification, time from injury to surgery, surgical approach, use of bone graft or bone substitute, and associated shoulder dislocation.

Fracture healing was assessed radiologically, and the time to union was categorized as within 12 weeks, 13–16 weeks, or more than 16 weeks. Union status was classified as union without delayed union, delayed union, or nonunion. Final radiographic alignment was categorized as acceptable alignment, varus malalignment, or other malalignment. Postoperative complications included screw penetration or cut-out, screw loosening, plate impingement, loss of reduction or fixation failure, avascular necrosis of the humeral head, surgical-site infection, and shoulder stiffness. Reoperation and the occurrence of at least one complication were also recorded.

Functional recovery was assessed using the Constant–Murley Score at 6 weeks and 3, 6, and 12 months after surgery. Mean scores and changes from the 6-week reference score were recorded. At final follow-up, functional outcomes were categorized as excellent (86–100), good (71–85), fair (56–70), or poor (below 56), according to the score categories specified in the study protocol. For association analysis, favorable outcomes comprised excellent and good results, while unfavorable outcomes comprised fair and poor results. Age, fracture pattern, union status, and complication status were evaluated in relation to final functional outcome.

Statistical Analysis

Data were entered, coded, and analyzed using IBM SPSS Statistics version 26. Continuous variables were summarized as mean ± standard deviation, while categorical variables were expressed as frequency and percentage. Functional scores at different follow-up intervals were summarized descriptively, and changes from the 6-week reference score were calculated. Associations between clinical factors and final functional outcome categories were assessed using the chi-square test or Fisher's exact test, as appropriate. A p-value of less than 0.05 was considered statistically significant.

RESULT

Among the 84 patients undergoing PHILOS plate fixation for proximal humerus fractures, the largest proportion were aged 40–59 years (46.43%), followed by those aged ≥60 years (33.33%) and 18–39 years (20.24%). Males constituted 60.71% of the patients, while 39.29% were females. Right-sided fractures occurred in 54.76% of cases. A fall from standing height was the predominant mechanism of injury (51.19%), followed by road traffic accidents (34.52%) and falls from height (14.29%). Hypertension was present in 23.81% and diabetes mellitus in 16.67%, whereas 59.52% had no documented comorbidity (*Table I*).

Table I
Sociodemographic and clinical characteristics of the patients (*n*=84).

Characteristics	Frequency (n=84)	Percentage (%)
Age group (years)		
18–39	17	20.24
40–59	39	46.43
≥60	28	33.33
Gender		
Male	51	60.71
Female	33	39.29
Affected side		
Right	46	54.76
Left	38	45.24
Mechanism of injury		
Fall from standing height	43	51.19
Road traffic accident	29	34.52
Fall from height	12	14.29
Comorbidities		
Diabetes mellitus	14	16.67
Hypertension	20	23.81
No documented comorbidity	50	59.52

Regarding fracture characteristics, three-part fractures were most common (42.86%), followed by two-part (34.52%) and four-part fractures (22.62%). Surgery was performed within seven days of injury in 72.62% of patients. The deltopectoral approach was used in 83.33%, while the deltoid-splitting approach was used in 16.67%. Bone graft or substitute was required in 11.90% of cases, and associated dislocation was documented in 13.10% (*Table II*).

Table II
Fracture characteristics and operative details (*n*=84).

Variables	Frequency (n=84)	Percentage (%)
Neer fracture classification		
Two-part fracture	29	34.52
Three-part fracture	36	42.86
Four-part fracture	19	22.62
Time from injury to surgery		
Within 7 days	61	72.62
More than 7 days	23	27.38
Surgical approach		
Deltopectoral	70	83.33
Deltoid-splitting	14	16.67
Bone graft or substitute used		
Yes	10	11.90
No	74	88.10
Associated dislocation		
Present	11	13.10
Absent	73	86.90

Radiological assessment demonstrated union without delayed union in 89.29% of patients, while delayed union and nonunion occurred in 7.14% and 3.57%, respectively. Radiological union was achieved within 12 weeks in 55.95% of patients and within 13–16 weeks in 32.14%; 7.14% required more than 16 weeks. Acceptable final alignment was observed in 90.48% of cases, whereas varus malalignment and other malalignment occurred in 5.95% and 3.57%, respectively (*Table III*).

Table III
Fracture union and radiological outcomes (*n*=84).

Radiological outcome	Frequency (n=84)	Percentage (%)
Time to radiological union		
Within 12 weeks	47	55.95
13–16 weeks	27	32.14
More than 16 weeks	6	7.14
Union status		
Union without delayed union	75	89.29
Delayed union	6	7.14
Nonunion	3	3.57
Final alignment		
Acceptable alignment	76	90.48
Varus malalignment	5	5.95

Other malalignment	3	3.57

At least one implant-related or postoperative complication occurred in 23.81% of patients. Shoulder stiffness was the most frequent complication (11.90%), followed by screw penetration or cut-out and plate impingement, each occurring in 5.95%. Loss of reduction or fixation failure was reported in 4.76%, while screw loosening, avascular necrosis of the humeral head, and surgical-site infection each occurred in 3.57%. Reoperation was required in 7.14% of patients (*Table IV*).

Table IV
Implant-related and postoperative complications (*n*=84).

Complication	Frequency (n=84)	Percentage (%)
Screw penetration or cut-out	5	5.95
Screw loosening	3	3.57
Plate impingement	5	5.95
Loss of reduction or fixation failure	4	4.76
Avascular necrosis of humeral head	3	3.57
Surgical-site infection	3	3.57
Shoulder stiffness	10	11.90
Reoperation required	6	7.14
Patients with at least one complication	20	23.81

The mean Constant–Murley Score increased from 46.80±9.70 at six weeks to 61.50±10.40 at three months, 70.90±11.30 at six months, and 75.20±12.10 at 12 months. The reported mean change from the six-week reference score reached 28.4 points at 12 months (*Table V*).

Table V
Functional recovery assessed by the Constant–Murley Score.

Follow-up interval	Mean score ± SD	Mean change from baseline
6 weeks	46.80 ± 9.70	Reference
3 months	61.50 ± 10.40	14.7
6 months	70.90 ± 11.30	24.1
12 months	75.20 ± 12.10	28.4

At final assessment, 38.10% of patients achieved a good functional outcome and 16.67% achieved an excellent outcome. Fair and poor outcomes were observed in 27.38% and 17.86%, respectively, indicating that 54.77% achieved good or excellent functional recovery (*Table VI*).

Table VI
Final functional outcome categories.

Functional outcome	Score	Frequency (n=84)	Percentage (%)
Excellent	86–100	14	16.67
Good	71–85	32	38.10
Fair	56–70	23	27.38
Poor	Below 56	15	17.86
Total		84	100.00

Using the Constant–Murley Score categories.

Association analysis showed no statistically significant relationship between functional outcome and age category (p=0.123) or fracture pattern (p=0.215). Union without delayed union was more frequent among patients with favorable outcomes than among those with unfavorable outcomes (95.65% vs. 81.58%; p=0.039). Similarly, the absence of complications was associated with favorable functional outcomes (84.78% vs. 65.79%; p=0.043). Conversely, delayed union or nonunion and the occurrence of at least one complication were more frequent in the unfavorable outcome group (18.42% and 34.21%, respectively) than in the favorable outcome group (4.35% and 15.22%, respectively) (*Table VII*).

Table VII
Association between clinical factors and final functional outcome.

Variable	Favorable outcome (n=46) n (%)	Unfavorable outcome (n=38) n (%)	p-value
Age			
Below 60 years	34 (73.91)	22 (57.89)	0.123
60 years or older	12 (26.09)	16 (42.11)	
Fracture pattern			
Two-part	19 (41.30)	10 (26.32)	0.215
Three-part	20 (43.48)	16 (42.11)	
Four-part	7 (15.22)	12 (31.58)	
Union status			
Union without delayed union	44 (95.65)	31 (81.58)	0.039
Delayed union or nonunion	2 (4.35)	7 (18.42)	
Complication status			
No complication	39 (84.78)	25 (65.79)	0.043
At least one complication	7 (15.22)	13 (34.21)	

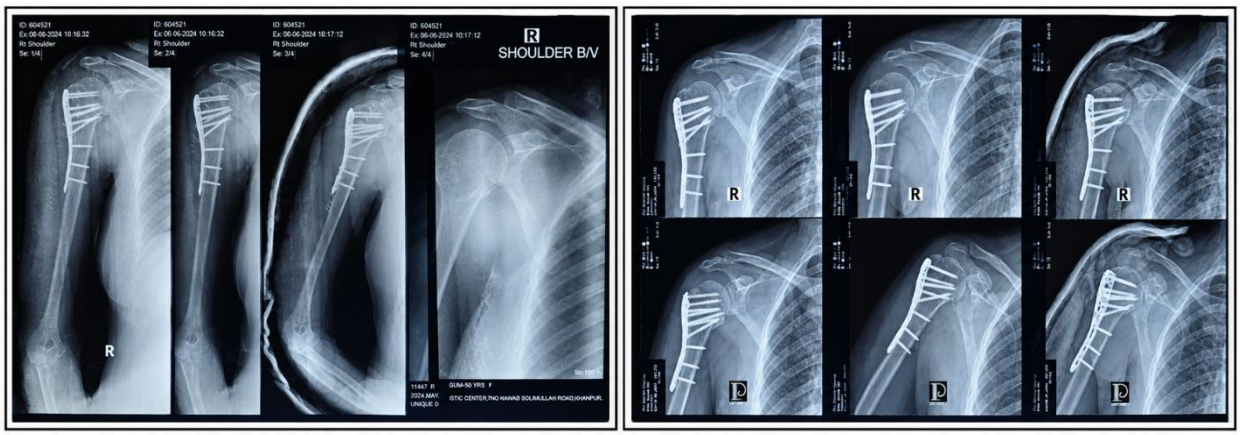

Figure 1: Post, Per and pre-operative picture for one study population.

DISCUSSION

Proximal humerus fractures are classified into two-part, three-part, and four-part fractures according to the Neer classification, with PHILOS plate fixation used to stabilize these fractures and facilitate healing and functional recovery [13]. The present study evaluated clinical, radiological, and functional outcomes following PHILOS plate fixation of proximal humerus fractures in 84 patients. The findings demonstrated satisfactory fracture union and progressive functional recovery, although postoperative complications and variations in final outcomes remained important concerns. Regarding sociodemographic characteristics, patients aged 40–59 years constituted the largest proportion (46.43%), and males accounted for 60.71% of participants. Falls from standing height were the predominant injury mechanism (51.19%). Moniruzzaman et al. reported a mean age of 49.1 ± 9.7 years, male predominance, and Fall on ground as the leading injury mechanism (63.3%). Their findings also identified three-part fractures as the most common pattern. These differences may reflect variations in patient characteristics and injury mechanisms across study populations [14]. Regarding fracture characteristics, three-part fractures predominated (42.86%), followed by two-part (34.52%) and four-part fractures (22.62%). A previous 59-patient study reported two-part and three-part fractures in 37.3% each and four-part fractures in 25.4% [15]. In the present study, the deltopectoral approach was used in 83.33% of patients, and 72.62% underwent surgery within seven days. However, the influence of surgical approach and timing on outcomes could not be established without comparative analyses. Radiological union occurred within 12 weeks in 55.95% of patients, while 89.29% achieved union without delayed healing. Acceptable final alignment was observed in 90.48%. Ethiraj et al. reported a mean fracture union time of 13.75 weeks in their 40-patient study [12]. Another 49-patient series reported union in all evaluable patients, with a mean union time of 12 weeks [16]. The present findings indicate satisfactory healing in most patients, although delayed union and nonunion occurred in 10.71% combined. Postoperative complications affected 23.81% of patients, with shoulder stiffness being the most frequent (11.90%). Screw penetration and plate impingement each occurred in 5.95%, while reoperation was required in 7.14%. Oldrini et al., in a systematic review and meta-analysis of 4,200 patients, reported an overall complication rate of 23.8% and a pooled reintervention rate of 10.5% [11]. The similar overall complication rates support the clinical relevance of implant-related problems following PHILOS fixation. The frequency of shoulder stiffness in the present study also emphasizes the importance of appropriate postoperative rehabilitation. Functional recovery improved progressively, with the mean Constant–Murley Score increasing from 46.80 ± 9.70 at six weeks to 75.20 ± 12.10 at 12 months. A 59-patient study reported a mean score of 71.25 ± 14.69 at six months, while Ethiraj et al. reported 68.75 ± 14.03 [12,15]. The higher final score in the present study may partly reflect the longer follow-up period. Regarding outcome categories, 54.77% achieved good or excellent results, whereas 45.24% had fair or poor outcomes. These findings indicate that satisfactory functional recovery was achieved in slightly more than half of the patients, with considerable individual variation. Finally, union status (p=0.039) and complication status (p=0.043) were significantly

associated with functional outcomes. Delayed union or nonunion and postoperative complications were more frequent among patients with unfavourable outcomes. In contrast, age (p=0.123) and fracture pattern (p=0.215) were not significantly associated with functional recovery. These findings suggest that fracture healing and complication prevention are important considerations in postoperative management, although causality cannot be established from these unadjusted associations [15].

LIMITATIONS

This study had several limitations. Its observational analytical design limits the ability to establish causal relationships between clinical factors and functional outcomes. The relatively small sample of 84 patients may have reduced the statistical power to detect associations, particularly for less frequent complications. Purposive sampling and the single-center setting may limit the generalizability of the findings to other populations and healthcare settings. Furthermore, follow-up was limited to 12 months, preventing assessment of long-term functional outcomes, late implant-related complications, and subsequent deterioration in shoulder function.

CONCLUSION

PHILOS plate fixation demonstrated satisfactory radiological and functional outcomes among patients with proximal humerus fractures. Radiological union without delayed healing was achieved in 89.29% of patients, while 90.48% maintained acceptable final alignment. At 12 months, the mean Constant–Murley Score improved to 75.20 ± 12.10, with 54.77% of patients achieving excellent or good functional outcomes. However, 23.81% experienced at least one postoperative complication, and 7.14% required reoperation. Delayed union or nonunion and postoperative complications were significantly associated with unfavorable functional outcomes. These findings emphasize the importance of achieving stable fixation, promoting fracture healing, preventing complications, and providing structured rehabilitation to optimize postoperative recovery.

FUNDING

No funding sources

CONFLICT OF INTEREST

None declared

ETHICAL APPROVAL

The study was approved by the Institutional Ethics Committee.

REFERENCES

1. Pandey R, Raval P, Manibanakar N, Nanjayan S, McDonald C, Singh H. Proximal humerus fractures: A review of current practice. Journal of clinical Orthopaedics and Trauma. 2023 Aug 1;43:102233.
2. Pencle F, Varacallo M. Proximal humerus fracture.
3. Nowak LL, Davis AM, Mamdani M, Beaton D, Schemitsch EH. A concept analysis and overview of outcome measures used for evaluating patients with proximal humerus fractures. Disability and Rehabilitation. 2021 May 8;43(10):1450-62.
4. Younis Z, Hamid MA, Amin J, Khan MM, Gurukiran G, Sapra R, Singh R, Wani KF, Younus Z, Younus Jr Z. Proximal humerus fractures: a review of anatomy, classification, management strategies, and complications. Cureus. 2024 Nov 5;16(11).
5. Martinez-Catalan N. Conservative treatment of proximal humerus fractures: when, how, and what to expect. Current reviews in musculoskeletal medicine. 2023 Feb;16(2):75-84.
6. Jabran A, Peach C, Ren L. Biomechanical analysis of plate systems for proximal humerus fractures: a systematic literature review. Biomedical engineering online. 2018 Apr 27;17(1):47.
7. Pimple M, Chidambaram R, Mok D. Long PHILOS plate fixation for complex humeral fractures. Shoulder & Elbow. 2010 Oct;2(4):255-8.
8. Sproul RC, Iyengar JJ, Devcic Z, Feeley BT. A systematic review of locking plate fixation of proximal humerus fractures. Injury. 2011 Apr 1;42(4):408-13.
9. Budharaju A, Hones KM, Hao KA, Wright JO, Fedorka CJ, Kaar SG, Bohsali KI, Wright TW, Patrick MR, King JJ. Rehabilitation protocols in proximal humerus fracture management: a systematic review. Shoulder & elbow. 2024 Jul;16(4):449-58.
10. Foruria AM. Plate fixation of proximal humerus fractures: how to get it right and future directions for improvement. Current Reviews in Musculoskeletal Medicine. 2023 Oct;16(10):457-69.
11. Oldrini LM, Feltri P, Albanese J, Marbach F, Filardo G, Candrian C. PHILOS synthesis for proximal humerus fractures has high complications and reintervention rates: a systematic review and meta-analysis. Life. 2022 Feb 19;12(2):311.
12. Ethiraj P, Venkataraman S, Shanthappa AH, Agarawal S, SJ K, Agrawal SS. Does proximal humerus inter locking system (PHILOS) plating provide a good functional outcome in proximal humerus fractures?. Cureus. 2022 Jun 30;14(6).
13. Carofino BC, Leopold SS. Classifications in brief: the Neer classification for proximal humerus fractures. Clinical Orthopaedics and Related Research®. 2013 Jan;471(1):39-43.
14. Moniruzzaman M, Das KP, Anjum S, Rahman MM, Ahmed SKM, Sanker M. A prospective study on functional and radiological outcome of PHILOS plating for the management of proximal humerus fracture. Int J Res Orthop. 2026;12:37-42.
15. Jain A, Bhalla N, Gangwar D, BHALLA N, GANGWAR D. Functional Outcome of Proximal Humerus Internal Locking System (PHILOS) Plating in Proximal Humerus Fractures. Cureus. 2025 May 28;17(5).
16. Gn KK, Gaurav S, Vijay S, Vaibhav J, Kamran F, Vivek M. Surgical treatment of proximal humerus fractures using PHILOS plate. Chinese journal of traumatology. 2014 Oct 1;17(05):279-84.