THE PLANET

Original Article

Comparative Outcomes Of Percutaneous Endoscopic Interlaminar Lumbar Discectomy Versus Open Lumbar Microdiscectomy For L5-S1 Lumbar Disc Herniation: A Retrospective Matched Cohort Study

Abul Fazal[1*], Mohammed Abdul Kadir[2], Ahasan Habib[3], Faisal Amin Ahmed[4], Rizwan Jamil[5], Mohammad Aminul Islam[6]

ARTICLE INFO

Received: 6 November 2026
Accepted: 16 November 2026
Published Online: 19 November 2026

DOI: 10.5281/zenodo.24356309

Volume: 10, Number: 3, Page: 1291-1296

e-ISSN: 2789-5912
ISSN: 2617-0817

*Corresponding author

ABSTRACT

Background: Lumbar disc herniation (LDH) at the L5-S1 level represents a significant cause of morbidity requiring surgical intervention when conservative treatment fails. **Objective:** To compare the clinical, surgical and radiological outcomes of percutaneous endoscopic interlaminar lumbar discectomy (PEILD) with open lumbar microdiscectomy (OLM) for L5-S1 LDH. **Methods & Materials:** A retrospective matched cohort analysis was conducted at the National Institute of Traumatology and Orthopaedic Rehabilitation, Dhaka, Bangladesh, between September 2023 and August 2025. Thirty-four patients (PEILD n=17; OLM n=17) underwent discectomy at L5-S1 with minimum one-year follow-up. Clinical outcomes including visual analogue scale (VAS) for back and leg pain, Oswestry Disability Index (ODI), and surgical parameters were evaluated. **Results:** The PEILD group demonstrated significantly lower immediate postoperative back pain (1.44±0.28 vs 2.41±0.27, P<0.001), shorter operative time (63.89±17.99 vs 109.66±31.42 minutes, P<0.001), reduced hospital stay (3.15±0.88 vs 5.72±1.44 days, P<0.001), and faster return to work (15.67±3.02 vs 24.31±4.68 days, P<0.001). Pain and functional outcomes at 12-month follow-up were comparable. Complication and recurrence rates did not differ significantly between groups. **Conclusion:** PEILD is a safe and effective alternative to OLM for L5-S1 LDH, with advantages in reduced postoperative morbidity and faster recovery.

Keywords: *Lumbar disc herniation; Percutaneous endoscopic interlaminar discectomy; Microdiscectomy; L5-S1; Retrospective cohort study*

1. *Assistant Professor, Spine Surgery, National Institute of Traumatology and Orthopaedic Rehabilitation (NITOR), Dhaka, Bangladesh. E-mail: (ORCID: 0009-0001-4374-2691)*
2. *Assistant Professor, Department of Orthopaedic Surgery, National Institute of Traumatology and Orthopaedic Rehabilitation (NITOR), Dhaka, Bangladesh (ORCID: 0009-0001-0655-7446)*
3. *Associate Professor, Department of Orthopaedic Surgery, National Institute of Traumatology and Orthopaedic Rehabilitation (NITOR), Dhaka, Bangladesh (ORCID: 0009-0005-4720-6043)*
4. *Assistant Professor, Orthopaedic Surgery, Shahid Jakir Hossain Border Guard Hospital, Pilkhana, Dhaka, Bangladesh (ORCID: 0009-0006-6834-4733)*
5. *Assistant Professor, Department of Orthopaedic Surgery, National Institute of Traumatology and Orthopaedic Rehabilitation (NITOR), Dhaka, Bangladesh (ORCID: 0009-0007-7591-3786)*
6. *Junior Consultant, Orthopaedic Surgery, National Institute of Traumatology and Orthopaedic Rehabilitation (NITOR), Dhaka, Bangladesh (ORCID: 0000-0001-9448-3530)*

INTRODUCTION

Lumbar disc herniation (LDH) is one of the most common spinal pathologies, affecting the lumbosacral region with a prevalence ranging from 5-20% in the general population[1].

The L5-S1 intervertebral disc level is particularly susceptible to herniation, representing the second most common site for disc herniation after the L4-L5 level[2].

The mechanical burden and anatomical characteristics of the L5-S1 junction make it a critical load-bearing region that frequently requires surgical intervention when conservative management fails to provide symptomatic relief[3].

Over the past two decades, minimally invasive surgical (MIS) techniques have emerged as the preferred modality for treating symptomatic LDH due to their reduced tissue trauma, lower morbidity, and accelerated recovery compared to traditional open approaches[4-6].

Among MIS techniques, percutaneous endoscopic interlaminar lumbar discectomy (PEILD) and open lumbar microdiscectomy (OLM) represent two prominent surgical approaches, each with distinct advantages and technical considerations[7].

While PEILD offers benefits including minimized soft tissue disruption, reduced blood loss, and rapid postoperative recovery, OLM remains a well-established technique with proven long-term safety and efficacy[8,9].

Limited comparative data from the South Asian region, particularly Bangladesh, are available regarding the outcomes of these two surgical techniques for L5-S1 LDH[10].

This retrospective matched cohort study was designed to compare the clinical, surgical, and radiological outcomes of PEILD versus OLM in patients with symptomatic L5-S1 LDH treated at a tertiary orthopaedic institution in Bangladesh.

METHODS & MATERIALS

STUDY DESIGN AND SETTING

This was an observational, retrospective matched cohort study conducted at the National Institute of Traumatology and Orthopaedic Rehabilitation (NITOR), Dhaka, Bangladesh. Clinical data were collected from September 2023 to August 2025. The study received institutional ethics approval and adhered to the principles of the Declaration of Helsinki.

PATIENT ENROLLMENT AND CRITERIA

Thirty-four patients with symptomatic L5-S1 LDH were enrolled and allocated to two groups: PEILD group (n=17) and OLM group (n=17). Inclusion criteria were: (1) age ≥18 years; (2) clinical symptoms of radiculopathy or intermittent neurogenic claudication for ≥6 months; (3) failed conservative treatment; (4) magnetic resonance imaging (MRI) confirmed L5-S1 central or paracentral LDH correlating with clinical symptoms. Exclusion criteria included: foraminal or extraforaminal LDH, previous spine surgery at the same level, psychiatric disorders, spinal comorbidities (isthmic or degenerative spondylolisthesis, spinal infection, oncologic disease), and

BDJOURNALS.ORG Copyright © 2026 The Planet. Published by Sher-E-Bangla Medical College, Barishal, Bangladesh. This is an open access article under the CC BY license (http://creativecommons.org/licenses/by/4.0/).

pathologies that might affect surgical outcomes.

BASELINE CHARACTERISTICS

Patient demographics, preoperative symptoms, radiological findings, and baseline functional status were recorded for both groups. Patients in both cohorts were matched for age, gender, and BMI to minimize selection bias.

SURGICAL TECHNIQUES

Percutaneous Endoscopic Interlaminar Lumbar Discectomy (PEILD): Procedures were performed under general anesthesia with the patient in prone position on a standard operating table. A 1-cm vertical skin incision was made medially at the interlaminar window, with intraoperative C-arm fluoroscopy guidance. Working cannulas were positioned with the beveled opening facing the medial facet. Bone resection using a diamond burr facilitated access to the interlaminar space. The ligamentum flavum was resected to expose the dural sac, and disc material was carefully removed under real-time endoscopic visualization with continuous isotonic saline irrigation. Annuloplasty was performed to repair the annular defect. Adequate decompression was confirmed by visualization of a tension-free nerve root with pulsatile movement[11,12].

Open Lumbar Microdiscectomy (OLM): Surgery was performed under general anesthesia. A small midline or paramedian incision was made at the L5-S1 level. The paraspinal muscles were retracted with a self-retaining retractor. Operating microscopy provided magnified visualization of the interlaminar window, ligamentum flavum, and neural structures. After ligamentum flavum removal and exposure of the dural sac, herniated disc material was carefully extracted using a combination of forceps and curette. Hemostasis was achieved, and the wound was closed in layers[13].

OUTCOME MEASURES

Primary outcomes: (1) Visual Analogue Scale (VAS) for back pain and leg pain (0-10 scale); (2) Oswestry Disability Index (ODI) scores for functional disability (0-100 scale, higher indicating greater disability); (3) Odom's criteria for clinical satisfaction (excellent/good/fair/poor).

Secondary outcomes: (1) Operative time (minutes); (2) Estimated blood loss (milliliters); (3) Hospital length of stay (days); (4) Return to work (days); (5) Radiological parameters including disc height, segmental lordosis, and lumbar lordosis at preoperative and final follow-up; (6) Complication rates (dural tear, nerve injury, infection); (7) Recurrent disc herniation rates; (8) Overall patient satisfaction (0-100%).

Outcome assessment was conducted at preoperative baseline, immediate postoperative period, and at 1, 3, 6, and 12 months postoperatively.

STATISTICAL ANALYSIS

Data were analyzed using standard descriptive statistics. Continuous variables were expressed as mean ± standard deviation (SD). Categorical variables were presented as frequencies and percentages. Comparison between groups was performed using independent t-tests for continuous variables and chi-square or Fisher's exact tests, as appropriate, for categorical variables. Statistical significance was defined as $P<0.05$.

RESULTS

PATIENT DEMOGRAPHICS AND BASELINE CHARACTERISTICS

A total of 34 patients were included in the study (PEILD n=17; OLM n=17; **Figure 1**). Baseline demographic and clinical characteristics are presented in *Table I*. The mean age was comparable between groups (PEILD 37.3±11.2 years vs OLM 39.8±9.7 years, P=0.492). Gender distribution showed no significant difference (P=1.000). Mean BMI was similar in both groups (PEILD 23.4±3.1 kg/m² vs OLM 24.1±3.8 kg/m², P=0.560). Preoperative VAS scores for back pain and leg pain, as well as ODI scores, were comparable between the two groups (P>0.05), confirming adequate matching.

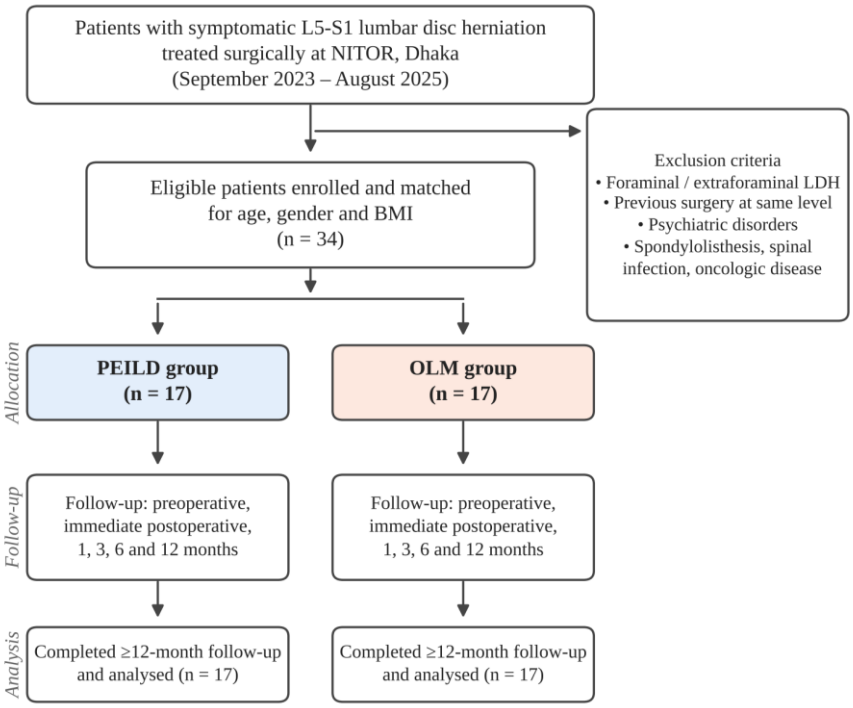

Figure 1: Flow Diagram of Patient Enrollment, Allocation, Follow-up and Analysis.

Table I
Baseline Demographic and Clinical Characteristics of Study Participants (*n*=34).

Variable	PEILD (n=17)	OLM (n=17)	P-value
Age (years)	37.3±11.2	39.8±9.7	0.492
Gender (M:F)	10:7	9:8	1.000
BMI (kg/m²)	23.4±3.1	24.1±3.8	0.560
VAS-Back (preop)	6.1±2.8	6.4±3.0	0.765
VAS-Leg (preop)	7.2±1.9	7.5±2.1	0.665
ODI (preop)	54.2±14.3	56.8±15.9	0.620
Follow-up (months)	12.5±2.1	12.8±2.3	0.694

Data are presented as mean ± SD or ratio. PEILD: percutaneous endoscopic interlaminar lumbar discectomy; OLM: open lumbar microdiscectomy; VAS: visual analogue scale; ODI: Oswestry Disability Index.
PEILD: percutaneous endoscopic interlaminar lumbar discectomy; OLM: open lumbar microdiscectomy; LDH: lumbar disc herniation; BMI: body mass index; NITOR: National Institute of Traumatology and Orthopaedic Rehabilitation.

PAIN AND FUNCTIONAL OUTCOMES

Both groups demonstrated significant improvements in pain scores from baseline to final follow-up. At immediate postoperative evaluation, the PEILD group showed significantly lower back pain (1.44±0.28 vs 2.41±0.27, P<0.001) compared to the OLM group. At 12 months postoperatively, VAS scores for back pain (0.9±0.4 vs 1.2±0.5, P=0.062) and leg pain (0.7±0.3 vs 0.8±0.4, P=0.416) were comparable between groups (**Table II**; **Figure 2**). ODI scores at final follow-up showed similar improvement in both groups (PEILD 12.3±4.2 vs OLM 14.1±5.3, P=0.281). Odom's criteria showed favorable outcomes in both groups at final follow-up (PEILD 88.2% excellent/good vs OLM 82.4% excellent/good, P=1.000).

Table II
Clinical Outcomes at Postoperative Follow-up.

Outcome Measure	PEILD (n=17)	OLM (n=17)	P-value
VAS-Back (12 mo)	0.9±0.4	1.2±0.5	0.062
VAS-Leg (12 mo)	0.7±0.3	0.8±0.4	0.416
ODI (12 mo)	12.3±4.2	14.1±5.3	0.281
Immediate Back Pain (VAS)	1.44±0.28	2.41±0.27	<0.001*
Odom's Excellent/Good (%)	88.2	82.4	1.000
Patient Satisfaction (%)	86.5±8.2	83.2±10.1	0.304
Recurrence Rate, n (%)	1 (5.9)	1 (5.9)	1.000

*Data are presented as mean ± SD or n (%). *Statistically significant (P<0.05).*

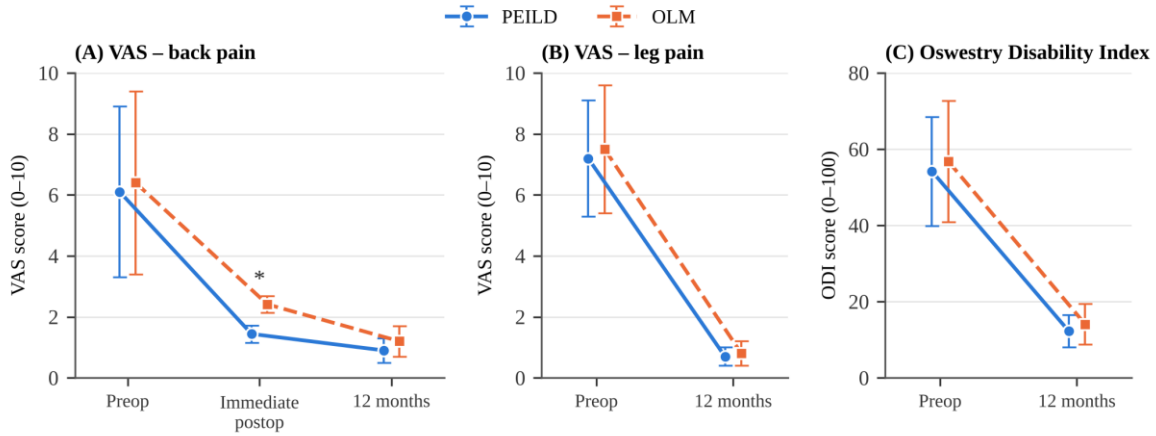

*Values are mean ± SD. (A) VAS for back pain at preoperative, immediate postoperative and 12-month assessment; (B) VAS for leg pain and (C) ODI at preoperative and 12-month assessment. *P<0.001 between groups. VAS: visual analogue scale; ODI: Oswestry Disability Index.*

Figure 2: Pain and Functional Outcomes from Baseline to 12-Month Follow-up.

SURGICAL OUTCOMES

The PEILD group demonstrated significant advantages in operative parameters (**Table III**; **Figure 3**). Mean operative time was significantly shorter in the PEILD group (63.89±17.99 vs 109.66±31.42 minutes, P<0.001). Estimated blood loss was markedly reduced in PEILD (22.4±8.3 mL vs 67.8±24.6 mL, P<0.001). Hospital length of stay was shorter in the PEILD group (3.15±0.88 vs 5.72±1.44 days, P<0.001). Return to work was significantly faster in PEILD (15.67±3.02 vs 24.31±4.68 days, P<0.001).

Table III
Surgical and Perioperative Outcomes.

Surgical Parameter	PEILD (n=17)	OLM (n=17)	P-value
Operative Time (min)	63.89±17.99	109.66±31.42	<0.001*
Blood Loss (mL)	22.4±8.3	67.8±24.6	<0.001*
Hospital Stay (days)	3.15±0.88	5.72±1.44	<0.001*
Return to Work (days)	15.67±3.02	24.31±4.68	<0.001*

*Data are presented as mean ± SD. *Statistically significant (P<0.05).*

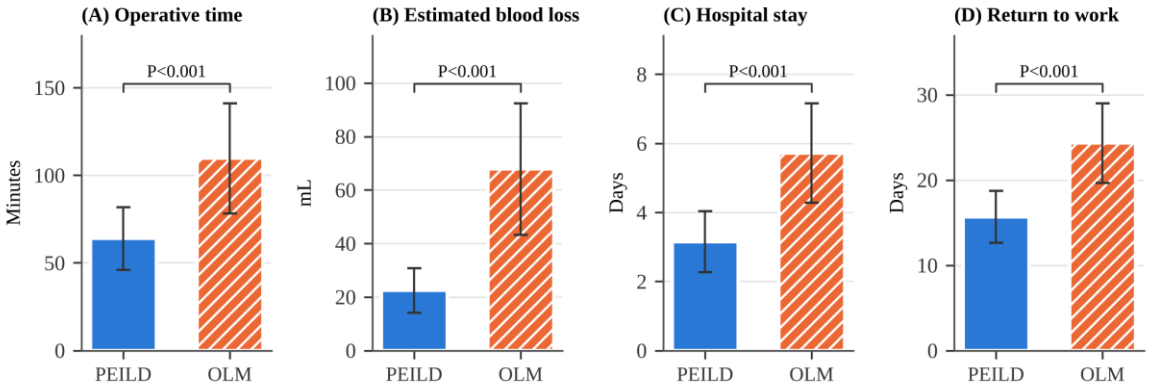

Bars show mean and error bars show SD. P-values by independent t-test. PEILD: percutaneous endoscopic interlaminar lumbar discectomy; OLM: open lumbar microdiscectomy.

Figure 3: Comparison of Surgical and Perioperative Outcomes between PEILD and OLM Groups.

RADIOLOGICAL OUTCOMES

Radiological parameters including disc height, segmental lordosis, and lumbar lordosis were comparable between groups at both preoperative and 12-month postoperative assessment. Preoperative disc height (PEILD 8.9±2.1 mm vs OLM 9.1±2.3 mm, P=0.793) and postoperative disc height (PEILD 9.2±2.0 mm vs OLM 9.4±2.2 mm, P=0.783) showed no significant intergroup differences. Segmental and lumbar lordosis measurements remained stable and comparable in both groups postoperatively (P>0.05).

COMPLICATIONS AND SAFETY

A total of 11 complication events were recorded in the PEILD group and 13 in the OLM group (**Table IV**). In the PEILD group, these comprised dural tear (n=2, 11.8%), transient dysesthesia (n=2, 11.8%), superficial wound infection (n=2, 11.8%), residual fragment (n=2, 11.8%), and one case each (5.9%) of discitis and hematoma. In the OLM group, dural tear (n=3, 17.6%) and superficial wound infection (n=3, 17.6%) were the most frequent, followed by transient dysesthesia (n=2, 11.8%), hematoma (n=2, 11.8%), and one case each (5.9%) of discitis and residual fragment. Recurrent disc herniation at the same level occurred in 1 patient in each group (5.9%) during the 12-month follow-up period. No nerve root injury, motor deficit or revision surgery occurred in either group. None of the differences between the groups was statistically significant (P=1.000 for all comparisons). All dural tears were small (<1 mm) pinhole tears and were recognised intraoperatively. In the PEILD group, they were managed with a Gelfoam/fibrin sealant patch without suture, and in the OLM group by primary suture repair; all patients were then kept on bed rest for 24–48 h, and none developed a cerebrospinal fluid (CSF) fistula or pseudomeningocele. Both cases of discitis were diagnosed at 2 weeks postoperatively on the basis of clinical features, raised erythrocyte sedimentation rate (ESR) and C-reactive protein (CRP), and magnetic resonance imaging (MRI) findings. Both were treated conservatively with intravenous antibiotics for 6 weeks followed by oral antibiotics for 6 weeks, together with a lumbar brace, and both resolved without surgical debridement.

Table IV
Postoperative Complications in the Study Population.

Complication	PEILD (n=17), n (%)	OLM (n=17), n (%)	P-value
Dural tear	2 (11.8)	3 (17.6)	1.000
Transient dysesthesia	2 (11.8)	2 (11.8)	1.000
Superficial wound infection	2 (11.8)	3 (17.6)	1.000
Discitis	1 (5.9)	1 (5.9)	1.000
Hematoma	1 (5.9)	2 (11.8)	1.000
Residual fragment	2 (11.8)	1 (5.9)	1.000
Recurrent disc herniation	1 (5.9)	1 (5.9)	1.000

Data are presented as n (%); percentages are calculated per group (n=17). A patient may have had more than one complication. P-values by Fisher's exact test.

DISCUSSION

This retrospective matched cohort study provides a direct comparison of PEILD and OLM for L5-S1 LDH in a South Asian population. The findings demonstrate that PEILD offers distinct advantages in terms of immediate postoperative recovery parameters while achieving comparable 12-month clinical outcomes with OLM[14].

The superior immediate postoperative pain relief and shorter operative time observed in the PEILD group align with previous studies highlighting the benefits of endoscopic techniques. The reduced operative time despite the minimally invasive nature of the procedure suggests technical proficiency and may reflect the rapid learning curve of experienced spine surgeons[15,16].

The significantly lower blood loss in PEILD (22.4 vs 67.8 mL) is consistent with the technique's reduced tissue disruption. The minimal exposure required for endoscopic access preserves paravertebral musculature and reduces surgical site trauma[17].

Hospital length of stay was substantially reduced in the PEILD group (3.15 vs 5.72 days), reflecting faster postoperative recovery. This reduction has significant implications for healthcare resource utilization and patient convenience. The accelerated return to work observed in PEILD (15.67 vs 24.31 days) translates to reduced productivity loss and improved socioeconomic outcomes for patients[18,19].

Notably, both techniques achieved comparable pain relief and functional improvement by 12 months postoperatively. The convergence of VAS and ODI scores between groups at final follow-up suggests that both approaches effectively address the underlying pathology, with differences primarily in the postoperative recovery trajectory rather than ultimate clinical efficacy. This finding is critical for surgical decision-making, as it indicates that choice of procedure may be individualized based on patient factors, surgeon expertise, and institutional capabilities[20].

Radiological preservation of disc height and spinal alignment was comparable between groups. The maintenance of disc height in both techniques supports the practice of conservative disc tissue handling, which may have implications for preventing adjacent-segment degeneration in long-term follow-up[21,22].

Complication rates did not differ significantly between the two techniques. However, the frequencies observed in this series, with dural tear in 11.8% of PEILD and 17.6% of OLM cases and superficial wound infection in 11.8% and 17.6%, respectively, are higher than those reported in larger series, where dural injury has been reported in approximately 2-6% of interlaminar endoscopic procedures and transient dysesthesia in 3-7% of patients[23]. Because a single event represents 5.9% of a group of 17 patients, these proportions are highly sensitive to individual events and should be interpreted with caution; the learning curve of the endoscopic technique may also have contributed[16]. In a meta-analysis of randomized trials, full-endoscopic discectomy was associated with fewer overall complications than open microdiscectomy (5.5% vs 10.4%), whereas pooled cohort studies showed a lower risk of dural injury but higher risks of transient dysesthesia, residual fragment and revision surgery with the endoscopic technique[18]. Consistent with these findings, residual fragment was numerically more frequent after PEILD in the present study (11.8% vs 5.9%), although the difference was not significant, and no revision surgery was required in either group. The recurrence rate of 5.9% in each group is in keeping with the 6.2% reported by Ruetten et al.[9] and with previous comparative series[24,25].

Limitations of this study include the retrospective design, relatively small sample size, single-institution experience, and short-term follow-up period. The small sample also limits the statistical power to detect differences in individual complications. The absence of long-term follow-up (>2 years) precludes assessment of reoperation rates and adjacent-segment degeneration. Additionally, cost-effectiveness analysis was not performed, which would be valuable for resource-constrained healthcare settings. Future prospective randomized trials with larger sample sizes and longer follow-up are warranted to definitively establish the superiority of either technique.

CONCLUSION

This retrospective matched cohort study demonstrates that PEILD is a safe and effective alternative to OLM for the treatment of L5-S1 central and paracentral lumbar disc herniation. The PEILD technique offers distinct advantages in immediate postoperative outcomes, including lower operative time, reduced blood loss, shorter hospital stays, and faster return to work. Importantly, both techniques achieve comparable pain relief and functional improvement at 12-month follow-up, with no significant difference in complication rates. These findings support the consideration of PEILD as a preferred approach for appropriately selected L5-S1 disc herniation cases, particularly in patients where rapid recovery and reduced perioperative morbidity are priorities. The choice between PEILD and OLM should be individualized based on patient factors, herniation characteristics, surgeon expertise, and institutional capabilities. Further prospective randomized controlled trials with larger sample sizes and extended follow-up periods are recommended to confirm these findings and establish definitive treatment algorithms.

CONFLICT OF INTEREST

The authors declare no competing financial, professional, or personal interests related to this manuscript.

FUNDING

This research received no specific grant from any public, commercial, or not-for-profit funding agency.

ACKNOWLEDGEMENT

The authors thank the teachers and faculty of NITOR, Dhaka, participating patients, hospital staff, colleagues, and all others who contributed to this study.

REFERENCES

1. Amin RM, Andrade NS, Neuman BJ. Lumbar disc herniation. Curr Rev Musculoskelet Med. 2017;10(4):507-516.
2. El-Rich M, Aubin CE, Villemure I, et al. A biomechanical study of L5-S1 low-grade isthmic spondylolisthesis using a personalized finite element model. Stud Health Technol Inform. 2006;123:431-434.
3. Lee BS, Walsh KM, Healy AT, et al. Biomechanics of L5/S1 in long thoracolumbosacral constructs: a cadaveric study. Global Spine J. 2018;8(6):607-614.
4. Kanno H, Aizawa T, Hashimoto K, et al. Minimally invasive discectomy for lumbar disc herniation: current concepts, surgical techniques, and outcomes. Int Orthop. 2019;43(4):917-922.
5. Yeung AT, Yeung CA. Minimally invasive techniques for the management of lumbar disc herniation. Orthop Clin North Am. 2007;38(3):363-372.
6. Chen KT, Jabri H, Lokanath YK, et al. The evolution of interlaminar endoscopic spine surgery. J Spine Surg. 2020;6(4):502-512.
7. Yeung AT, Tsou PM. Posterolateral endoscopic excision for lumbar disc herniation: surgical technique, outcome, and complications in 307 consecutive cases. Spine (Phila Pa 1976). 2002;27(7):722-731.
8. Mayer HM, Brock M. Percutaneous endoscopic discectomy: surgical technique and preliminary results compared to microsurgical discectomy. J Neurosurg. 1993;78(2):216-225.
9. Ruetten S, Komp M, Merk H, Godolias G. Full-endoscopic interlaminar and transforaminal lumbar discectomy versus conventional microsurgical technique: a prospective, randomized, controlled study. Spine (Phila Pa 1976). 2008;33(9):931-939.
10. Liu Y, Kim Y, Park CW, Suvithayasiri S, Jitpakdee K, Kim JS. Interlaminar endoscopic lumbar discectomy versus microscopic lumbar discectomy: a preliminary analysis of L5-S1 lumbar disc herniation outcomes in prospective randomized controlled trials. Neurospine. 2023;20(4):1457-1468.
11. Choi G, Lee SH, Raiturker PP, Lee S, Chae YS. Percutaneous endoscopic interlaminar discectomy for intracanalicular disc herniations at L5-S1 using a rigid working channel endoscope. Neurosurgery. 2006;58(1 Suppl):ONS59-68.
12. Khandge AV, Kim JS. Modified interlaminar endoscopic lumbar discectomy for highly upmigrated disc

herniation: a proctorship description of the technique via translaminar route. Neurospine. 2020;17(Suppl 1):S66-73.
13. Osterman H, Seitsalo S, Karppinen J, et al. Effectiveness of microdiscectomy for lumbar disc herniation: a randomized controlled trial with 2 years of follow-up. Spine (Phila Pa 1976). 2006;31(21):2409-2414.
14. Dasenbrock HH, Juraschek SP, Schultz LR, et al. The efficacy of minimally invasive discectomy compared with open discectomy: a meta-analysis of prospective randomized controlled trials. J Neurosurg Spine. 2012;16(5):452-462.
15. Akinduro OO, Kerezoudis P, Alvi MA, et al. Open versus minimally invasive surgery for extraforaminal lumbar disk herniation: a systematic review and meta-analysis. World Neurosurg. 2017;108:924-938.
16. Hsu HT, Chang SJ, Yang SS, et al. Learning curve of full-endoscopic lumbar discectomy. Eur Spine J. 2013;22(4):727-733.
17. Hasan S, Härtl R, Hofstetter CP. The benefit zone of full-endoscopic spine surgery. J Spine Surg. 2019;5(Suppl 1):S41-56.
18. Yang CC, Chen CM, Lin MHC, Huang WC, Lee MH, Kim JS, et al. Complications of full-endoscopic lumbar discectomy versus open lumbar microdiscectomy: a systematic review and meta-analysis. World Neurosurg. 2022;168:333-348.
19. Lee SG. Why should we perform endoscopic spine surgery? Neurospine. 2020;17(Suppl 1):S13-S14.
20. Simpson AK, Lightsey HM 4th, Xiong GX, et al. Spinal endoscopy: evidence, techniques, global trends, and future projections. Spine J. 2022;22(1):64-74.
21. Bae J, Kim J, Lee SH, et al. Comparative analysis of transforaminal endoscopic thoracic discectomy and microscopic discectomy for symptomatic thoracic disc herniation. Neurospine. 2022;19(4):555-562.
22. Kwon H, Park JY. The role and future of endoscopic spine surgery: a narrative review. Neurospine. 2023;20(1):43-55.
23. National Institute for Health and Care Excellence. Percutaneous interlaminar endoscopic lumbar discectomy for sciatica. Interventional procedures guidance [IPG555]. London: NICE; 2016.
24. Fujita M, Inui T, Oshima Y, Iwai H, Inanami H, Koga H. Comparison of the outcomes of microendoscopic discectomy versus full-endoscopic discectomy for the treatment of L4/5 lumbar disc herniation. Global Spine J. 2024;14(3):922-929.
25. Jitpakdee K, Liu Y, Kotheeranurak V, Kim JS. Transforaminal versus interlaminar endoscopic lumbar discectomy for lumbar disc herniation: a systematic review and meta-analysis. Global Spine J. 2023;13(2):575-587.