THE PLANET

Original Article

Surgical Management of Posterior Acetabular Wall Fracture-Dislocation: Prospective Evaluation of Functional and Radiological Outcomes

S M Raqibul Hasan[1*], Faisal Amin Ahmed[2], Abul Fazal[3], Tapas Mandal[4], Mohd Tareq Anwar Shishir[5], Rokonuzzaman[6]

ARTICLE INFO

Received: 28 October 2026
Accepted: 02 November 2026
Published Online: 08 November 2026

DOI: 10.5281/zenodo.24047240

Volume: 10, Number: 3, Page: 1253-1257

e-ISSN: 2789-5912
ISSN: 2617-0817

*Corresponding author

ABSTRACT

Background: Posterior acetabular wall fractures with hip dislocation are complex injuries. This study evaluated clinical and radiological outcomes after operative treatment.**Objectives:** To assess functional and radiographic outcomes after open reduction and internal fixation (ORIF) of posterior acetabular wall fractures with hip dislocation. **Methods & Materials:** Twenty-five patients (mean age 38.68±11.82 years) with posterior wall fractures and hip dislocation were enrolled from March 2020 to September 2022. All underwent closed reduction followed by fixation through a Kocher-Langenbeck approach with reconstruction plating. Function was assessed using the Modified Merle d'Aubigne and Postel score, and radiographs using Matta's criteria. **Results:** At 6 months, 16 patients (64%) had excellent and 5 (20%) good functional outcomes (84% favorable). Radiographically, 18 (72%) had excellent joint appearance, 4 (16%) good, 1 (4%) fair, and 2 (8%) poor. Anatomical reduction was achieved in 18 (72%) and satisfactory reduction in 6 (24%). Complications included femoral head avascular necrosis in 2 (8%), iatrogenic sciatic nerve injury in 1 (4%; resolved by 6 weeks), and heterotopic ossification in 2 (8%). No wound infections or deep vein thrombosis occurred. **Conclusions:** Operative treatment yielded favorable functional and radiological outcomes. Reduction quality and stable fixation appear to be important determinants of clinical success.

Keywords: *Acetabular fractures, posterior wall, hip dislocation, open reduction internal fixation, functional outcomes.*

1. *Assistant Professor, Sports Medicine and Arthroscopy, National Institute of Traumatology and Orthopaedic Rehabilitation (NITOR), Dhaka, Bangladesh (ORCID: 0009-0008-2113-6130)*
2. *Assistant Professor, Orthopedic Surgery, Shahid Jakir Hossain Border Guard Hospital, Pilkhana, Dhaka, Bangladesh (ORCID: 0009-0006-6834-4733)*
3. *Assistant Professor, Spine Surgery, National Institute of Traumatology and Orthopaedic Rehabilitation (NITOR), Dhaka, Bangladesh (ORCID: 0009-0001-4374-2691)*
4. *Assistant Registrar, Orthopaedic Surgery, Gopalgonj Medical College Hospital, Bangladesh (ORCID: 0009-0007-8134-0240)*
5. *Assistant Surgeon (Orthopaedic), Orthopaedic Surgery, National Institute of Traumatology and Orthopaedic Rehabilitation (NITOR), Dhaka, Bangladesh (ORCID: 0009-0005-3417-9648)*
6. *Assistant Professor, Orthopaedic Surgery, Chuadanga Sador Hospital, Bangladesh (ORCID: 0009-0008-9496-3022)*

INTRODUCTION

Hip dislocation with concurrent acetabular fracture constitutes an orthopedic emergency with substantial morbidity and disability potential[1]. Posterior wall fractures comprise approximately 23-25% of all acetabular injuries, with posterior hip dislocation occurring in up to 84% of these cases[2]. High-velocity mechanisms, predominantly motor vehicle collisions, typically generate these injuries. Contemporary operative management emphasizes anatomic reduction and rigid fixation to prevent secondary osteoarthritis and preserve hip biomechanical integrity[3-4].

The optimal surgical management of these complex injuries remains subject to debate regarding timing, approach selection, and fixation methodology. Evidence indicates that reduction quality, rather than temporal factors, predominantly influences long-term functional outcomes[5]. This investigation presents a prospective evaluation of operative outcomes in a consecutive patient series.

OBJECTIVES

To evaluate functional and radiological outcomes following open reduction and internal fixation of posterior acetabular wall fractures associated with posterior hip dislocation.

METHODS & MATERIALS

Study Design and Patient Selection

This prospective, single-institutional cohort study enrolled patients presenting with posterior wall acetabular fractures combined with posterior hip dislocation. The institutional ethics board approved the protocol. Informed written consent was obtained from all participants.

Inclusion Criteria:

- Age 18-60 years
- Radiographically confirmed posterior wall acetabular fracture with posterior hip dislocation
- Surgical intervention completed within 21 days of injury
- Minimum 6-month clinical follow-up completed

Exclusion Criteria:

- Open fractures
- Pathological fractures
- Pre-existing pelvic infection
- Concurrent fractures of other anatomical sites

Patient Cohort

Twenty-five patients satisfied inclusion criteria during the 30-month enrollment period (March 2020 – September 2022). Demographic characteristics included mean age 38.68±11.82 years (range 18-58 years), with 24 males (96%) and 1 female (4%). Occupational distribution revealed drivers comprised 32% (n=8), followed by service workers (24%, n=6), students (20%, n=5), farmers (12%, n=3), and businesspersons (8%, n=2).

Injury Mechanism and Timeline

Road traffic accidents constituted the primary injury mechanism in 23 patients (92%), with fall from height accounting for 2 cases (8%). Mean interval between injury and hip reduction was 7.28±3.80 hours (range 2-16 hours). The majority (56%) underwent closed reduction within 6 hours, while 32% required 7-12 hours and 12% required 13-24 hours post-injury.

Surgical Intervention

All patients received closed hip reduction under conscious sedation or general anesthesia at emergency presentation, followed by skeletal traction. Definitive

BDJOURNALS.ORG Copyright © 2026 The Planet. Published by Sher-E-Bangla Medical College, Barishal, Bangladesh. This is an open access article under the CC BY license (http://creativecommons.org/licenses/by/4.0/).

operative intervention was performed after patient optimization, with mean interval of 12.64±4.142 days post-injury. The Kocher-Langenbeck posterior approach was utilized uniformly across all cases, facilitating direct visualization of the posterior column and wall. Fixation was accomplished using reconstruction plates supplemented by spring plates in comminuted cases. Mean operative time was 98±18 minutes.

Outcome Measures:

Functional Assessment

Functional outcomes were evaluated using the Modified Merle d'Aubigne and Postel scoring system, incorporating three parameters:

- Pain (range 0-6)
- Gait function (range 0-6)
- Range of motion (range 0-6)

Total score ranges 0-18: Excellent ≥18, Good 15-17, Fair 13-14, Poor <13

Radiological Evaluation

Post-operative radiographic assessment employed Matta's classification system:

- Anatomical reduction: ≤1mm displacement
- Satisfactory reduction: 2-3mm displacement
- Unsatisfactory reduction: >3mm displacement

Radiographic outcome grading:

- Excellent: Normal-appearing hip joint
- Good: Mild degenerative changes, minimal joint narrowing
- Fair: Moderate degenerative changes, moderate narrowing <50%
- Poor: Advanced changes, severe narrowing >50%, femoral head collapse

Follow-up Protocol

Clinical assessment occurred at 2, 6, 12, and 24 weeks post-operatively. Radiographic evaluation was performed at identical intervals. Final outcome assessment was conducted at 6 months.

Statistical Analysis

Data analysis utilized IBM SPSS Statistics Version 22 (SPSS Inc., Chicago, IL, USA). Descriptive statistics were computed for demographic and clinical variables. Categorical variables were expressed as frequencies and percentages. Continuous variables were reported as mean ± standard deviation. Paired t-tests assessed changes in functional scores across follow-up intervals. Chi-square analysis with Yates continuity correction evaluated radiographic outcome distribution at 12 and 24-week intervals. P-values <0.05 were considered statistically significant.

RESULTS

Demographic and Injury Characteristics

The study cohort demonstrated male predominance (96%), reflecting the higher incidence of high-energy trauma in males within our geographic region. Mean patient age was 38.68±11.82 years, with the largest proportion (32%) occupying the fourth decade of life. Road traffic accidents accounted for 92% of injuries, consistent with epidemiological patterns from high-traffic urban centers.

Hip Reduction Timeline

Closed hip reduction was successfully accomplished in all 25 patients. The mean interval between injury and hip reduction was 7.28±3.80 hours. Early reduction (≤6 hours) was achieved in 56% of patients (n=14), primarily those transported directly to our facility. Delayed reduction (>6 hours) in the remaining cases primarily reflected late hospital presentation due to geographic distance or prehospital transportation constraints.

Operative Timeline and Hospitalization

Mean interval between injury and definitive operative fixation was 12.64±4.142 days (range 7-21 days). The majority of patients (72%, n=18) underwent surgery within 8-14 days, allowing for adequate pre-operative optimization and resolution of soft tissue swelling. Mean hospital length of stay was 15.84±4.394 days (range 8-28 days). Extended hospitalization in some cases reflected delayed mobilization or minor wound management complications.

Fracture Reduction Quality

Radiographic assessment immediately post-operatively demonstrated anatomical reduction (≤1mm displacement) in 18 patients (72%), satisfactory reduction (2-3mm) in 6 patients (24%), and unsatisfactory reduction (>3mm) in 1 patient (4%). The single case with unsatisfactory reduction involved comminuted fragments with marginal impaction; this patient subsequently developed early avascular necrosis of the femoral head and underwent total hip arthroplasty at 18 months post-injury.

Post-operative Complications

Twenty patients (80%) experienced uncomplicated post-operative courses. Avascular necrosis of the femoral head developed in 2 patients (8%) at 12-week follow-up, confirmed on magnetic resonance imaging and advanced radiographic staging. Both cases involved posterior dislocation with prolonged reduction delays (>10 hours) or occurred despite anatomical fracture reduction, suggesting vascular disruption from the initial injury mechanism.

Iatrogenic sciatic nerve injury (neuropraxia) occurred in 1 patient (4%), attributed to excessive traction during soft tissue mobilization. This case demonstrated complete resolution of motor and sensory deficits by 6-week follow-up.

Heterotopic ossification (Brooker Grade I-II) developed in 2 patients (8%), managed conservatively without functional compromise.

No cases of wound infection, deep vein thrombosis, or pulmonary embolism occurred.

Functional Outcomes

At 6-month final follow-up assessment, excellent functional outcomes (Modified Merle d'Aubigne score 18) were achieved in 16 patients (64%), good outcomes (15-17) in 5 patients (20%), fair outcomes (13-14) in 2 patients (8%), and poor outcomes (<13) in 2 patients (8%). Composite favorable outcomes (excellent + good) totaled 84%.

Pain Assessment

The majority of patients (19, 76%) reported complete pain resolution. Slight or intermittent pain persisted in 4 patients (16%), and 2 patients (8%) experienced post-ambulation pain that resolved with rest.

Gait Function

Seventeen patients (68%) demonstrated normal gait mechanics. Four patients (16%) ambulated without assistive device but with mild limp. Three patients (12%) required cane or crutch for long-distance ambulation. One patient (4%) demonstrated limited gait with support, secondary to the aforementioned avascular necrosis case requiring hip arthroplasty.

Range of Motion

Hip range of motion recovery was substantial: 20 patients (80%) achieved 95-100% of normal motion, 3 patients (12%) demonstrated 80-94% motion, and 2 patients (8%) achieved 70-79% motion.

Radiological Outcomes at 6 Months

Radiographic assessment at 6-month follow-up revealed excellent hip joint appearance in 18 patients (72%), consistent with normal or near-normal joint anatomy and no degenerative changes. Good outcomes (mild changes, small osteophytes, minimal narrowing <1mm) occurred in 4 patients (16%). Fair outcomes (moderate degenerative changes, narrowing <50%) were observed in 1 patient (4%). Poor outcomes (severe degenerative changes, narrowing >50%) were documented in 2 patients (8%), both occurring in patients with suboptimal initial reduction or early avascular necrosis. Serial radiographs obtained preoperatively and at three- and six-month follow-up are shown in Figure 1.

Radiographic scores demonstrated significant improvement from 12-week to 24-week follow-up intervals (Chi-square = 4.821, p = 0.024), with 18 patients exhibiting excellent outcomes at final assessment compared to 8 at 12-week evaluation.

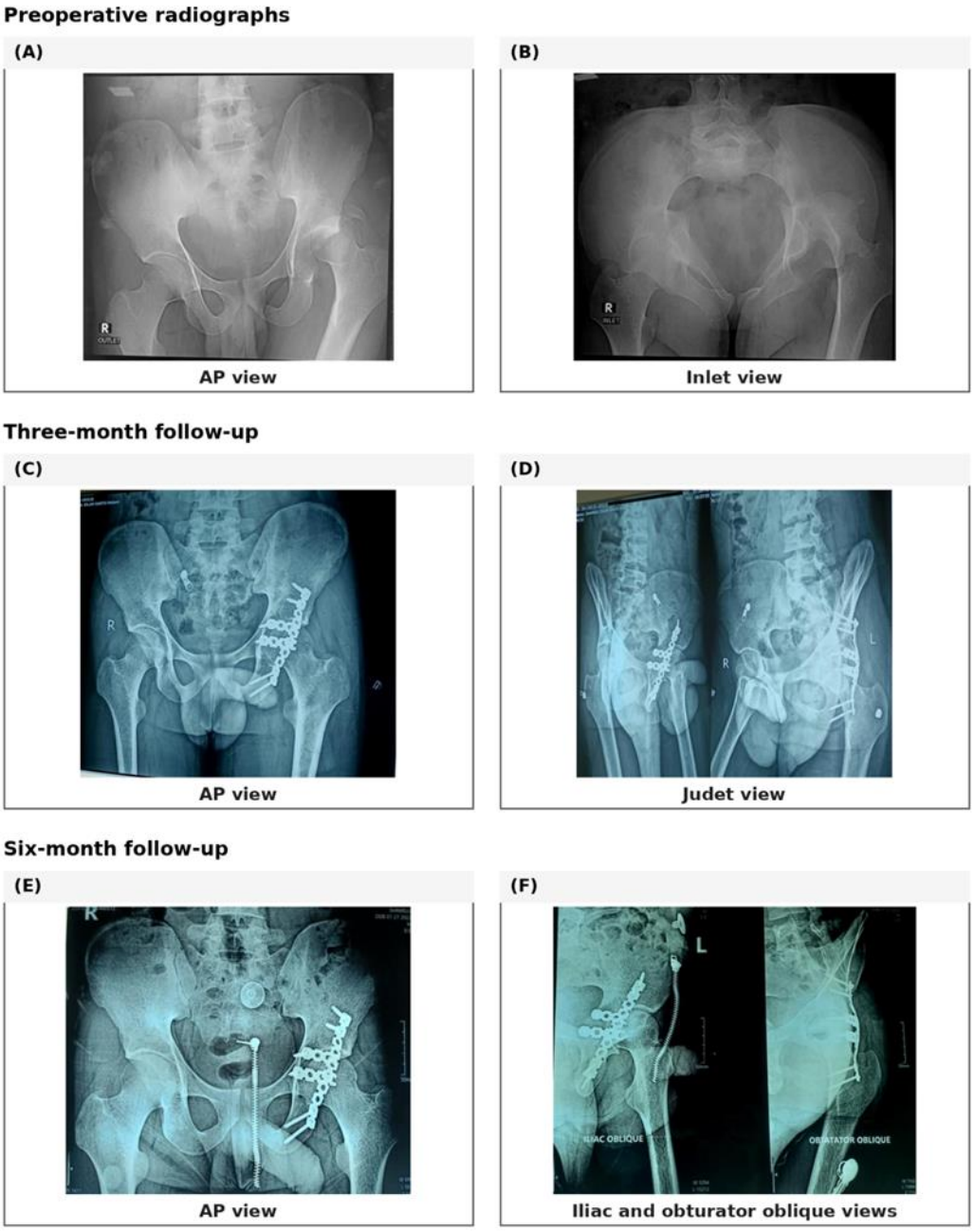

Figure 1. Serial radiographic assessment following open reduction and internal fixation (ORIF) of a posterior acetabu wall fracture-dislocation. (A) Preoperative anteroposterior (AP) pelvic radiograph; (B) preoperative inlet view. (C, D) Three-month follow-up radiographs showing the AP and Judet views, respectively. (E, F) Six-month follow-up radiographs showing the AP view and iliac and obturator oblique views, respectively.

Temporal Evolution of Functional Scores

Functional outcome scores demonstrated progressive improvement across the follow-up period:

- 6-week mean score: 14.21 ± 1.68
- 12-week mean score: 15.22 ± 1.82 (p = 0.04, paired t-test)
- 24-week mean score: 16.96 ± 1.79 (p = 0.02, paired t-test)

Statistical analysis revealed significant improvement between 12-week and 24-week assessments (paired t-test, p = 0.02), indicating continued functional recovery within the 6-month period.

DISCUSSION

This prospective investigation represents one of the limited series from South Asian trauma centers evaluating operative outcomes in posterior wall acetabular fractures-dislocations. The 84% favorable functional outcome rate aligns with contemporary international literature, wherein most series report good-to-excellent results in 74-89% of surgically managed cases[6-8].

Reduction Quality as the Primary Outcome Determinant

Matta and colleagues' seminal work demonstrated an inverse relationship between reduction displacement and clinical outcome, establishing <1mm displacement as the target for anatomical reduction[3]. Our series achieved anatomical reduction in 72% of cases, comparable to modern results (70-92%) and substantially improved from historical rates of 40-60% in the 1980s. The single unsatisfactory reduction case experienced early avascular necrosis and required hip arthroplasty, providing clinical validation for the critical importance of reduction precision.

Notably, time from injury to operative intervention did not significantly influence outcome in our cohort, consistent with Bhandari and colleagues' conclusions that reduction quality supersedes temporal considerations[4]. However, time to initial closed hip reduction did correlate with avascular necrosis development in our series: one case with 11-hour reduction delay developed AVN despite adequate fracture reduction, while another with 4-hour reduction also developed AVN, suggesting that vascular disruption from the injury mechanism itself may be the predominant factor in AVN pathogenesis[11].

Operative Approach and Fixation Strategy

The Kocher-Langenbeck approach was uniformly employed in our series, providing excellent visualization of the posterior column and wall anatomy. This approach is considered the gold standard for posterior wall fractures, achieving anatomical reduction in up to 92% of cases when technical expertise is optimal[12]. Our 72% anatomical reduction rate reflects the complexity of our case selection and indicates room for technique refinement with accumulated experience.

The use of reconstruction plating supplemented by spring plating in comminuted cases proved effective, with no cases of loss of reduction on follow-up imaging. This fixation strategy aligns with current recommendations emphasizing buttress plating for posterior wall stability[13].

Complication Profile

The iatrogenic sciatic nerve injury rate of 4% in our series falls below the reported range of 2-8% in meta-analytic data, and notably, our single case resolved completely by 6 weeks without permanent sequelae[14]. This favorable resolution likely reflects careful nerve identification and gentle manual retraction without mechanical retractor placement.

The avascular necrosis rate of 8% exceeds some contemporary series (3-5%) but falls within the reported range of 5-9% for posterior dislocation cases[15]. The higher rate in our cohort may reflect the combination of high-energy injury mechanism and delayed reduction in some cases. Importantly, neither AVN case developed within the first 6 weeks, consistent with AVN being a late sequela occurring over weeks to months rather than immediately post-operatively.

Heterotopic ossification at 8% is lower than the meta-analytic incidence of 25.6% reported by Giannoudis and colleagues, though prophylactic measures were not routinely employed in our series[5]. This favorable rate may reflect the specific characteristics of our patient population or the reduced soft tissue trauma associated with careful surgical technique.

Functional Recovery Trajectory

The progressive improvement in functional scores across the follow-up period, with significant gains between 12 and 24 weeks, suggests that patients continue meaningful functional recovery throughout the 6-month period. Extended rehabilitation and physical therapy protocols likely contributed to this progressive improvement. The 80% of patients achieving 95-100% hip range of motion indicates excellent functional mobility restoration, supporting the efficacy of our rehabilitation protocol.

Methodological Considerations

This study was conducted at a tertiary trauma center with dedicated pelvic and acetabular surgery expertise. Results may not be generalizable to centers with limited experience in acetabular surgery, where complication rates and suboptimal reduction rates are substantially higher[17]. The relatively small sample size (n=25) reflects the specific case selection (posterior wall + posterior dislocation) but may limit power for detecting differences in subgroup analyses.

The 6-month follow-up period captures early outcome data but cannot assess long-term sequelae such as late post-traumatic osteoarthritis, which may develop over years to decades. Longer-term follow-up studies would provide insight into durability of outcomes.

CONCLUSIONS

Operative management via open reduction and internal fixation using the Kocher-Langenbeck approach and reconstruction plating yields favorable functional and radiological outcomes in the majority of patients with posterior wall acetabular fractures-dislocations. Anatomical fracture reduction emerged as the most critical determinant of outcome, independent of time-to-surgery considerations. Quality surgical technique, careful soft tissue handling, and appropriate implant selection were essential to achieve optimal results. Centers managing acetabular fractures should prioritize dedicated training and maintenance of expertise in pelvic trauma surgery to optimize patient outcomes.

CONFLICT INTERESTS

The authors declare no competing financial, professional, or personal interests related to this manuscript.Funding:

FUNDING

This research received no specific grant from any public, commercial, or not-for-profit funding agency.

ACKNOWLEDGMENTS

The authors thank the teachers and faculty of NITOR, Dhaka, participating patients, hospital staff, colleagues, and all others who contributed to this study.

REFERENCES

1. Ahmed M, Abuodeh Y, Alhammoud A, et al. Epidemiology of acetabular fractures in Qatar. Int Orthop. 2018;42(9):2211-2217.
2. Pascarella R, Cerbasi S, Politano R, et al. Surgical results and factors influencing outcome in patients with posterior wall acetabular fracture. Injury. 2017;48(8):1819-1824.
3. Matta JM. Fractures of the acetabulum: accuracy of reduction and clinical results in patients managed operatively within three weeks after the injury. J Bone Joint Surg Am. 1996;78(11):1632-1645.
4. Bhandari M, Matta J, Ferguson T, Matthys G. Predictors of clinical and radiological outcome in patients with fractures of the acetabulum and concomitant posterior dislocation of the hip. J Bone Joint Surg Br. 2006;88(12):1618-1624.
5. Giannoudis PV, Grotz MR, Papakostidis C, Dinopoulos H. Operative treatment of displaced fractures of the acetabulum. A meta-analysis. J Bone Joint Surg Br. 2005;87(1):2-9.
6. Mitsionis GI, Lykissas MG, Motsis E, et al. Surgical management of posterior hip dislocations associated with posterior wall acetabular fracture: a study with a minimum follow-up of 15 years. J Orthop Trauma. 2012;26(8):460-465.
7. Rice J. Does high velocity mechanism of injury and the degree of hip dislocation severity predict outcomes following open reduction and internal fixation of acetabular fractures? J Trauma. 2007;63(4):774-778.
8. Kachnerkar NI, Markade P. Study and results of reconstruction plating in fracture posterior column and posterior wall of acetabulum. Int J Res Orthop. 2017;3(6):1104-1110.
9. Matta JM. Operative treatment of acetabular fractures through the ilioinguinal approach. A 10-year perspective. Clin Orthop Relat Res. 1994; 305:10-19.
10. Tannast M, Najibi S, Matta JM. Two to twenty-year survivorship of the hip in 810 patients with operatively treated acetabular fractures. J Bone Joint Surg Am. 2012;94(17):1559-1567.
11. Ziran N, Soles G, Matta JM. Outcomes after surgical treatment of acetabular fractures: a review. Patient Saf Surg. 2019; 13:16.
12. Magu NK, Gogna P, Singh A, et al. long-term results after surgical management of

posterior wall acetabular fractures. J Orthop Traumatol. 2014;15(3):173-179.
13. Pease F, Ward AJ, Stevenson AJ, et al. Posterior wall acetabular fracture fixation: A mechanical analysis of fixation methods. J Orthop Surg. 2019;27(3):2309499019848813.
14. Middlebrooks ES, Sims SH, Kellam JF, Bosse MJ. Incidence of sciatic nerve injury in operatively treated acetabular fractures without somatosensory evoked potential monitoring. J Orthop Trauma. 1997;11(5):327-329.
15. Hougaard K, Thomsen PB. Traumatic posterior dislocation of the hip--prognostic factors influencing the incidence of avascular necrosis of the femoral head. Arch Orthop Trauma Surg. 1986;106(1):32-35.
16. Guerado E, Cano JR, Cruz E. Fractures of the acetabulum in elderly patients: an update. Injury. 2012;43(Suppl): S33-S41.
17. Tosun HB, Serbest S, Gümüştaş SA, et al. Learning curve for surgical treatment of acetabular fractures: a retrospective clinical study of a practical and theoretical training course. Med Sci Monit. 2017; 23:5218-5225.