

Evaluating the Diagnostic Accuracy of Computed Tomography for Non-Neoplastic and Neoplastic Sinonasal Lesions

Salma Khatun^{1*}, Faruk Hossen², Faria Gaffar³, Shraboni Roy⁴, Polash Kumar Sarkar⁵, Noushin Huda⁶

ARTICLE INFO

Received: 20 June 2026
Accepted: 25 June 2026
Published Online: 30 June 2026

DOI: 10.5281/zenodo.21078678

Volume: 9, Number: 4, Page: 258-263

e-ISSN: 2789-5912
ISSN: 2617-0817

*Corresponding author



ABSTRACT

Background: Sinonasal lesions comprise a wide spectrum of inflammatory and neoplastic conditions that often present with overlapping clinical features, making accurate diagnosis challenging. Computed tomography (CT) plays a crucial role in evaluating these lesions by providing detailed anatomical information and aiding in disease characterization. **Objective:** To evaluate the diagnostic accuracy of CT in differentiating non-neoplastic and neoplastic sinonasal lesions and to correlate CT findings with histopathological diagnosis. **Methods & Materials:** This cross-sectional observational study was conducted in the Department of Radiology and Imaging, Shaheed Suhrawardy Medical College Hospital, Dhaka, over six months. A total of 100 patients with clinically suspected sinonasal masses were included. All patients underwent CT examination followed by histopathological evaluation, which served as the gold standard. Diagnostic performance of CT was assessed by calculating sensitivity, specificity, positive predictive value (PPV), negative predictive value (NPV), and overall accuracy. **Results:** The majority of patients were male (83%) with a mean age of 45.3 ± 9.7 years. CT revealed non-neoplastic lesions in 73% and neoplastic lesions in 27% of cases. Histopathology confirmed 75% non-neoplastic, 14% benign, and 11% malignant lesions. CT showed good correlation with histopathology, with sensitivity of 88.1%, specificity of 72.0%, PPV of 90.4%, and NPV of 66.7%. The overall diagnostic accuracy was approximately 84%. **Conclusion:** CT is a reliable imaging modality for evaluating sinonasal lesions and provides high diagnostic accuracy in differentiating non-neoplastic and neoplastic conditions. However, histopathology remains essential for definitive diagnosis.

Keywords: Sinonasal lesions, Computed tomography, Histopathology, Diagnostic accuracy, Nasal mass.

1. Junior Consultant, Radiology & Imaging (OSD), Directorate General of Health Services (DGHS), Attached to Maternal, Neonatal, Child Health (MNCH) Project, Dhaka, Bangladesh (ORCID: 0009-0002-5644-7568)
2. Assistant Professor, Department of Radiology & Imaging, 250 Bedded District Sadar Hospital, Shariatpur, Bangladesh (ORCID: 0009-0006-8199-0414)
3. Junior Consultant, Department of Radiology & Imaging, Parliament Medical Centre, Dhaka, Bangladesh (ORCID: 0009-0007-6269-5812)
4. Medical Officer, Department of Radiology & Imaging, Shaheed Suhrawardy Medical College & Hospital, Dhaka, Bangladesh (ORCID: 0009-0005-2365-7560)
5. Radiologist, Department of Radiology & Imaging, Sadar Hospital, Satkhira, Bangladesh (ORCID: 0009-0005-4636-1041)
6. Assistant Professor, Department of Radiology and Imaging, National Institute of Traumatology and Orthopaedic Rehabilitation (NITOR), Dhaka, Bangladesh (ORCID: 0009-0002-3147-8747)

INTRODUCTION

Sinonasal lesions encompass a heterogeneous group of pathological conditions involving the nasal cavity and paranasal sinuses. These lesions include a wide range of disorders, extending from inflammatory and infective processes to benign and malignant neoplasms. Because of the complex anatomy of the sinonasal region and the overlap of clinical manifestations among different disease entities, accurate diagnosis often remains challenging. Inflammatory conditions, particularly nasal polyps, constitute the majority of sinonasal lesions encountered in clinical practice. Previous studies have reported that simple inflammatory nasal polyps represent the most common histopathological diagnosis among sinonasal masses, whereas malignant lesions account for only a small proportion of cases. Nevertheless, the prompt recognition of malignant disease is essential because early diagnosis significantly improves treatment outcomes and long-term survival.^[1,2]

Tumors arising from the sinonasal tract are relatively uncommon and contribute to approximately 3% of all head and neck malignancies and nearly 1% of all tumors occurring throughout the body. Despite their rarity, these lesions are clinically important because of their potential for local invasion and involvement of critical adjacent structures. Sinonasal neoplasms may originate from a variety of tissues, including the Schneiderian mucosa, minor salivary glands, neural elements, lymphoid tissue, and mesenchymal structures. Their clinical presentation is often nonspecific, with symptoms such as nasal obstruction, rhinorrhea, epistaxis, facial pain, and headache frequently mimicking those of chronic inflammatory sinonasal diseases. Consequently, differentiation between neoplastic and non-neoplastic lesions based solely on clinical findings is often difficult.^[3-5]

Accurate assessment of sinonasal pathology requires a multidisciplinary approach involving clinical examination, nasal endoscopy, imaging studies, and histopathological evaluation. Advances in

imaging technology have substantially improved the diagnostic workup of sinonasal diseases and have contributed significantly to treatment planning. In pediatric and adult patients alike, imaging plays a pivotal role in identifying lesion extent, evaluating skull base involvement, and assessing possible intracranial or orbital extension. Such information is crucial for staging disease and determining the most appropriate therapeutic strategy.^[6] Radiological evaluation is particularly important because many sinonasal diseases present with similar symptoms despite having markedly different pathological characteristics and prognoses. Imaging provides valuable information regarding lesion location, extent, tissue characteristics, and adjacent structural involvement that may not be apparent on physical examination or endoscopy. Therefore, radiological investigations have become an indispensable component of the diagnostic pathway for sinonasal disorders.^[7,8] Historically, conventional radiography was widely used in the assessment of sinonasal

diseases. However, its inability to accurately depict detailed sinonasal anatomy and disease extent has greatly limited its diagnostic value. The development of cross-sectional imaging techniques has revolutionized sinonasal imaging, with computed tomography (CT) largely replacing plain radiographs as the primary imaging modality. This transition has been driven by the increasing demand for precise anatomical information, particularly in patients undergoing endoscopic surgical procedures.^[9,10]

Computed tomography is currently regarded as the imaging modality of choice and the gold standard for the evaluation of sinonasal pathology. It provides excellent visualization of air-filled spaces, mucosal abnormalities, bony structures, and anatomical variations. Modern multidetector CT (MDCT) scanners offer high-resolution images that facilitate accurate assessment of sinonasal drainage pathways and help identify factors contributing to disease development. Moreover, CT enables visualization of anatomical structures that may not be accessible through endoscopic examination, thereby providing critical information for both diagnosis and surgical planning.^[11,12]

Another major advantage of CT is its ability to delineate the extent of disease and identify aggressive features suggestive of neoplastic processes, including bone erosion, osseous destruction, extranasal extension, and local tissue invasion. Although magnetic resonance imaging (MRI) provides superior soft-tissue characterization and is particularly useful for evaluating orbital and intracranial extension, CT remains superior in demonstrating fine bony details and fibro-osseous lesions of the paranasal sinuses.^[12] Furthermore, CT offers detailed three-dimensional visualization of sinonasal anatomy and disease distribution, making it highly valuable in the assessment of chronic and recurrent sinonasal disorders.^[13]

Computed tomography also plays a fundamental role in preoperative assessment for Functional Endoscopic Sinus Surgery (FESS). Coronal CT images closely resemble the endoscopic surgical view and facilitate accurate identification of important anatomical landmarks. Detailed preoperative evaluation helps surgeons recognize anatomical variations that may increase the risk of intraoperative complications and thereby contributes to safer surgical intervention and improved patient outcomes.^[14,15]

The combined use of CT and diagnostic nasal endoscopy has become the cornerstone of contemporary sinonasal disease evaluation. By providing comprehensive anatomical and pathological information, CT contributes

significantly to diagnosis, treatment planning, and postoperative follow-up.^[16] However, despite its excellent imaging capabilities, histopathological examination remains the definitive method for establishing the nature of sinonasal lesions. Therefore, correlating CT findings with histopathological diagnoses is essential for determining the true diagnostic performance of CT.

In view of these considerations, the present study aims to evaluate the diagnostic accuracy of computed tomography in differentiating non-neoplastic and neoplastic sinonasal lesions. The study further seeks to correlate CT findings with histopathological examination and endoscopic findings, where available, and to determine the sensitivity, specificity, and overall diagnostic efficacy of CT in the assessment of sinonasal diseases.

OBJECTIVES

The objective of this study was to diagnostic accuracy of Computed Tomography (CT) in the assessment of non-neoplastic and neoplastic sinonasal lesions.

METHODS & MATERIALS

The cross-sectional observational study was conducted in the Department of Radiology and Imaging, Shaheed Suhrawardy Medical College Hospital, Dhaka, Bangladesh. The study was carried out over a period of six months from July 2018 to 12th January 2019.

Sample Selection

Inclusion criteria

- Age 18 years and above
- Both male and female patients
- Patients presenting with clinically suspected sinonasal mass
- Patients undergoing CT scan of paranasal sinuses
- Patients who provided consent for histopathological examination

Exclusion criteria

- Age below 18 years
- Critically ill patients unfit for CT scan or biopsy
- Patients who refused CT scan or histopathological examination
- Incomplete clinical, imaging or histopathological data

Data Collection Procedure

A total of 100 patients with clinically suspected sinonasal masses were initially enrolled in the study. After applying inclusion and exclusion criteria, all eligible patients underwent computed tomography (CT) of the paranasal sinuses in the Department of Radiology and Imaging, Shaheed Suhrawardy Medical College Hospital.

CT scans were performed using a 128-slice multidetector CT scanner (Hitachi Scenaria). Imaging findings were evaluated by experienced radiologists. The diagnosis of sinonasal lesions was made based on CT characteristics such as site of origin, extent of disease, pattern of sinus involvement, bone erosion or remodeling, density of lesion, and evidence of extranasal extension.

Following radiological assessment, histopathological examination (HPE) was performed for all cases, which served as the gold standard for final diagnosis. CT findings were then correlated with histopathological results to evaluate diagnostic accuracy.

Baseline data including age, sex, occupation, and clinical presentation were recorded using a semi-structured questionnaire. Each patient was assigned a unique identification number to maintain confidentiality. Written informed consent was obtained from all participants prior to enrollment.

Ethical Considerations

Ethical approval was obtained from the Institutional Ethical Review Committee of Shaheed Suhrawardy Medical College Hospital. Written informed consent was obtained from all patients prior to participation. Confidentiality of patient information was strictly maintained, and all data were used exclusively for research purposes in accordance with the Declaration of Helsinki.

Statistical Analysis

Statistical analysis was performed using IBM SPSS Statistics software. Quantitative variables were expressed as mean \pm standard deviation, while categorical variables were presented as frequency and percentage. Association between CT findings and histopathological diagnosis was analyzed using the Chi-square test. Diagnostic performance of CT was assessed by calculating sensitivity, specificity, positive predictive value (PPV), negative predictive value (NPV), and overall accuracy, using histopathology as the gold standard. A p-value of less than 0.05 was considered statistically significant.

RESULTS

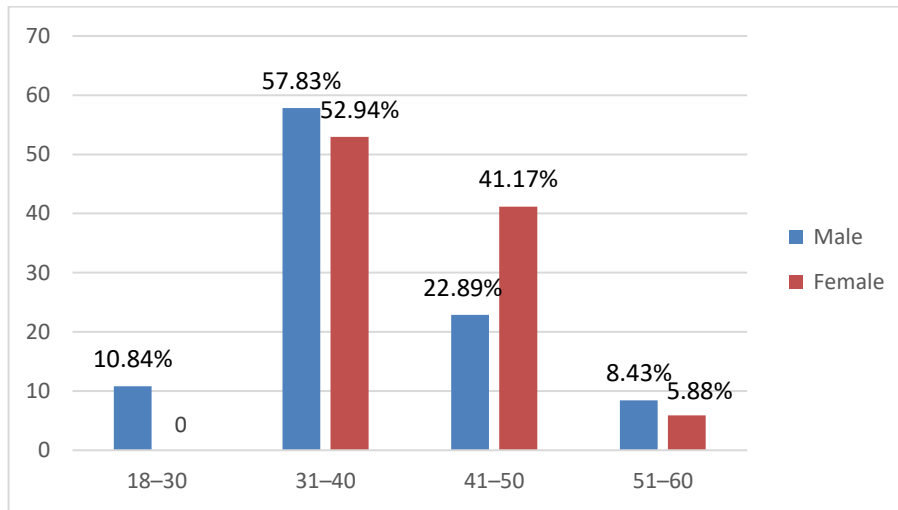


Figure 1 Demographic characteristics of the study population (n=100).

Figure 1 shows that the majority of patients were in the age group of 31-40 years (57%), followed by 41-50 years (26%). The mean age of the study

population was 45.3 ± 9.7 years. Male patients were predominant in all age groups, with the highest frequency also observed in the 31-40-year age group.

Overall, 83% of the patients were male and 17% were female.

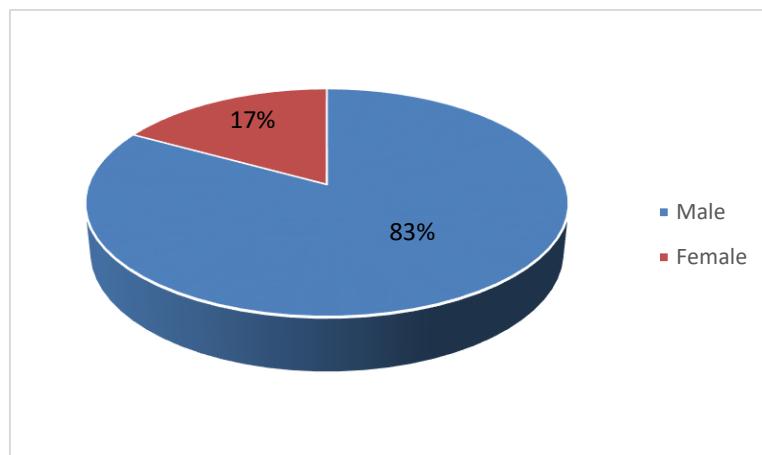


Figure 2 Gender distribution of the study population (n=100).

Figure 2 shows that the study population was predominantly male, comprising 83% of cases, while female patients accounted for 17%. The male-to-female ratio was 4.88:1, indicating a strong male

predominance among patients with sinonasal lesions. Table I shows that nasal obstruction was the most common clinical presentation, observed in 78% of patients, followed by headache (62%) and nasal discharge

(57%). Other less frequent symptoms included facial swelling (27%), epistaxis (23%), proptosis with visual impairment (16%), diplopia (12%), facial asymmetry (9%), and hearing disturbance (9%).

Table I

Clinical presentation of sinonasal lesions (n=100).

Clinical features	Frequency	Percentage %
Nasal obstruction	78	78%
Headache	62	62%
Nasal discharge	57	57%
Facial swelling	27	27%
Epistaxis	23	23%
Proptosis / visual impairment	16	16%
Diplopia	12	12%
Facial asymmetry	9	9%
Hearing disturbance	9	9%

Table II shows that based on CT evaluation, non-neoplastic lesions were the

most common, accounting for 73% of cases. Among these, allergic sinonasal

polyps were the most frequent subtype (43%), followed by inflammatory polyps

(17%), rhinoscleroma (8%), and rhinosporidiosis (5%). Benign neoplastic lesions constituted 18% of cases, with

inverted papilloma and capillary haemangioma being common. Malignant lesions were identified in 9% of cases, with

squamous cell carcinoma being the most frequent malignant subtype.

Table II

CT diagnosis of sinonasal lesions (n=100)

Category	Subtype	Frequency	Percentage %
Non-neoplastic	Allergic sinonasal polyp	43	43%
	Inflammatory polyp	17	17%
	Rhinoscleroma	8	8%
	Rhinosporidiosis	5	5%
	Angiofibroma	3	3%
Benign neoplastic	Inverted papilloma	6	6%
	Capillary haemangioma	6	6%
	Fibrous dysplasia	2	2%
	Mucocele	1	1%
	Squamous cell carcinoma	5	5%
Malignant	Adenocarcinoma	1	1%
	Undifferentiated carcinoma	3	3%

Table III shows that histopathological examination revealed that 75% of cases were non-neoplastic lesions. Among these, allergic polyps were most common (41%),

followed by inflammatory polyps (21%), rhinoscleroma (9%), and rhinosporidiosis (4%). Benign neoplastic lesions accounted for 14% of cases, with capillary

haemangioma being the most frequent (7%). Malignant lesions constituted 11% of cases, with squamous cell carcinoma being the most common malignant tumor (7%).

Table III

Histopathological diagnosis of sinonasal lesions (n=100).

Category	Subtype	Frequency	Percentage %
Non-neoplastic	Allergic polyp	41	41%
	Inflammatory polyp	21	21%
	Rhinoscleroma	9	9%
	Rhinosporidiosis	4	4%
	Angiofibroma	2	2%
Benign neoplastic	Inverted papilloma	4	4%
	Capillary haemangioma	7	7%
	Fibrous dysplasia	1	1%
	Squamous cell carcinoma	7	7%
Malignant	Adenocarcinoma	3	3%
	Undifferentiated carcinoma	1	1%

Table IV shows that comparison between CT findings and histopathological diagnosis revealed good concordance. Out of 73 cases diagnosed as non-neoplastic on

CT, 66 were confirmed as non-neoplastic on histopathology, while 7 were found to be neoplastic. Similarly, among 27 CT-diagnosed neoplastic cases, 18 were

confirmed as neoplastic on histopathology, while 9 were non-neoplastic.

Table IV

Comparison of CT findings with histopathological diagnosis (n=100).

CT diagnosis	HPE Non-neoplastic	HPE Neoplastic	Total
Non-neoplastic	66	7	73
Neoplastic	9	18	27
Total	75	25	100

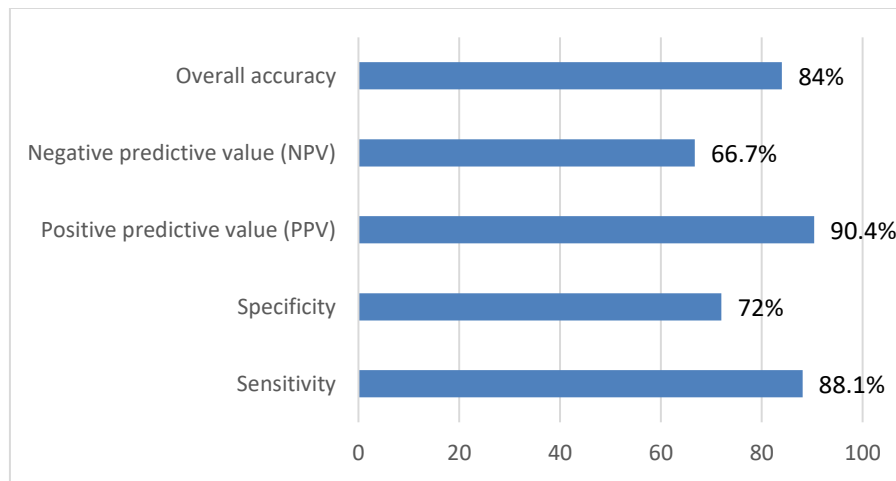


Figure 3 Diagnostic performance of CT in sinonasal lesions ($n=100$).

Figure 3 shows that computed tomography demonstrated good diagnostic performance in evaluating sinonasal lesions when compared with histopathology. The sensitivity was 88.1%, indicating high ability to correctly identify disease. Specificity was 72.0%, reflecting moderate accuracy in identifying non-disease cases. The positive predictive value was 90.4%, while the negative predictive value was 66.7%. The overall diagnostic accuracy of CT was approximately 84%, suggesting that CT is a reliable imaging modality for the assessment of sinonasal lesions.

DISCUSSION

The present study was conducted to evaluate the diagnostic accuracy of computed tomography (CT) for assessing non-neoplastic and neoplastic sinonasal lesions and to correlate CT findings with histopathological diagnoses. The study also aimed to determine the sensitivity, specificity, and overall diagnostic performance of CT in sinonasal masses. In this study, the majority of patients were aged 31–40 years (57%), with a mean age of 45.3 ± 9.7 years. Male predominance was observed, with 83% male and 17% female patients, resulting in a male-to-female ratio of 4.88:1. These findings are consistent with studies conducted by Harika Surapaneni et al. and Nepal A et al., which also demonstrated male predominance and similar age distribution patterns in sinonasal diseases.^{17,18} Bist S et al. also reported comparable demographic trends with a slight variation in gender ratio.¹⁹ The higher incidence in middle-aged males may be attributed to increased exposure to environmental pollutants, occupational hazards, and healthcare-seeking behavior. Regarding clinical presentation, nasal obstruction (78%), headache (62%), and nasal discharge (57%) were the most common symptoms in the present study. These findings are consistent with previous studies where nasal obstruction and headache were the

predominant complaints among patients with sinonasal lesions.²⁰ The nonspecific nature of these symptoms often leads to delayed diagnosis, particularly in cases of malignant sinonasal tumors. Sinonasal malignancies are known to present late due to their similarity with chronic rhinosinusitis in the early stages. Early symptoms such as nasal obstruction, rhinorrhea, and epistaxis are frequently overlooked by both patients and clinicians. With disease progression, symptoms such as visual disturbances, facial swelling, and cranial nerve involvement may appear, indicating advanced disease.^{21,22} This highlights the importance of imaging in early detection and disease characterization. In the present study, CT evaluation revealed that non-neoplastic lesions were the most common (73%), followed by neoplastic lesions (27%), of which 18% were benign and 9% were malignant. Among non-neoplastic lesions, allergic sinonasal polyps (43%) were the most frequent, followed by inflammatory polyps (17%), rhinoscleroma (8%), and rhinosporidiosis (5%). These findings are in agreement with studies reporting inflammatory lesions as the predominant sinonasal pathology.¹⁹ Among neoplastic lesions, inverted papilloma and capillary haemangioma were common benign tumors, while squamous cell carcinoma was the most frequent malignant lesion. Similar observations have been reported in previous studies where inverted papillomas and osteomas were common benign lesions, and squamous cell carcinoma accounted for the majority of malignant sinonasal tumors.^{21,22} This distribution reflects the known epidemiological pattern of sinonasal neoplasms. Histopathological analysis in the present study demonstrated that 75% of cases were non-neoplastic, 14% were benign neoplastic, and 11% were malignant lesions. Among non-neoplastic lesions, allergic polyps were most common (54.7%), followed by inflammatory polyps (28%), rhinoscleroma

(12%), and rhinosporidiosis (5.3%). These findings are comparable with previous studies reporting inflammatory lesions as the most frequent histological diagnosis in sinonasal masses.²³ CT plays a crucial role in differentiating inflammatory from neoplastic lesions and in assessing lesion extent. In the present study, CT correctly identified 66 non-neoplastic and 18 neoplastic cases when compared with histopathology. However, some misclassification was observed, with 7 neoplastic lesions appearing as non-neoplastic on CT and 9 non-neoplastic lesions being interpreted as neoplastic. This demonstrates that although CT is highly useful, overlap in imaging features can lead to diagnostic discrepancies. The overall diagnostic performance of CT in the present study showed a sensitivity of 88.1%, specificity of 72.0%, positive predictive value of 90.4%, and negative predictive value of 66.7%. These findings indicate that CT has high sensitivity and good positive predictive value in identifying sinonasal lesions, making it a reliable modality for initial evaluation. The statistical association between CT and histopathological findings was significant ($p = 0.001$), indicating strong diagnostic relevance. Similar results have been reported in previous studies, where CT demonstrated high sensitivity and specificity in diagnosing sinonasal diseases compared to clinical evaluation.¹ Chronic sinusitis has been reported with sensitivity and specificity as high as 98.3% and 97.8%, respectively, while benign and malignant lesions also show high diagnostic accuracy. CT is particularly useful in identifying malignant lesions with sensitivity above 90% in many studies.¹ Dean et al. (2019) highlighted that despite advances in imaging, biopsy and histopathological evaluation remain the definitive methods for diagnosis because many sinonasal tumors lack pathognomonic imaging characteristics.²³ CT is also superior in evaluating bony

structures and detecting aggressive disease features such as bone erosion, destruction, and extrasinus extension. In fungal sinusitis, CT sensitivity has been reported to be lower in early disease but significantly higher in detecting invasive changes, including bone involvement, where specificity approaches nearly 100%.²⁴ This makes CT particularly valuable in surgical planning and in assessing disease extent. Furthermore, CT plays an essential role in preoperative assessment for functional endoscopic sinus surgery (FESS) by providing detailed anatomical mapping of sinonasal structures. This helps surgeons identify anatomical variations, avoid intraoperative complications, and improve surgical outcomes. The ability of CT to provide a surgical roadmap further strengthens its role as the imaging modality of choice in sinonasal disease evaluation. Overall, the present study demonstrates that CT is a highly effective imaging modality for evaluating sinonasal masses, particularly in differentiating non-neoplastic from neoplastic lesions and in guiding clinical and surgical management. However, histopathology remains the gold standard for definitive diagnosis, and CT findings should always be interpreted in correlation with histopathological results.

CONCLUSION

Computed tomography (CT) is a highly valuable imaging modality in the evaluation of sinonasal lesions. It provides excellent anatomical detail and plays a crucial role in differentiating non-neoplastic from neoplastic lesions, assessing lesion extent, and guiding preoperative planning. In this study, CT demonstrated good diagnostic performance with high sensitivity and satisfactory specificity when compared with histopathological findings, which remain the gold standard for definitive diagnosis. The overall findings of the study indicate that CT is an effective and reliable first-line imaging tool for sinonasal masses, particularly in identifying disease extent and aiding surgical decision-making. However, due to overlapping imaging features among different pathological entities, histopathological confirmation is essential for accurate final diagnosis. Therefore, CT should always be used in conjunction with clinical and pathological correlation to ensure optimal patient management.

ACKNOWLEDGMENT

I would like to express my sincere gratitude for the invaluable support and cooperation provided by the staff, participants and my co-authors/colleagues who contributed to this study.

CONFLICTS OF INTEREST

There are no conflicts of interest.

ETHICAL APPROVAL

The study was approved by the Institutional Ethics Committee.

REFERENCES

- Kandukuri R, Phatak S. Evaluation of sinonasal diseases by computed tomography. *J Clin Diagn Res.* 2016 Nov;10(11):TC09–TC12.
- Bakari A, Afolabi O, Adoga A, Kodiya A, Ahmad B. Clinico-pathological profile of sinonasal masses: an experience in National Ear Care Centre Kaduna, Nigeria. *BMC Res Notes.* 2010;3:186–189.
- Alabi BS, Afolabi OA, Omokanye HK, Dunmade AD, Ayodele SO. Clinical presentation and outcome of sinonasal tumour in a Nigerian tertiary hospital: 6-year review. *Niger Med J.* 2017;58(3):92–95.
- Goepfert H, Luna MA, Lindberg RD, White AK. Malignant salivary gland tumours of the paranasal sinuses and nasal cavity. *Arch Otolaryngol.* 1983;109:662–668.
- Osguthorpe JD. Sinus neoplasia. *Arch Otolaryngol Head Neck Surg.* 1994;120:19–25.
- Lloyd C, McHugh K. The role of radiology in head and neck tumours in children. *Cancer Imaging.* 2010;10:49–61.
- Zinreich JS. Functional anatomy and computed tomography imaging of the paranasal sinuses. *Am J Med Sci.* 1998;316(1):2–12.
- Mafee MF. Endoscopic sinus surgery: role of the radiologist. *AJNR Am J Neuroradiol.* 1991;12(5):855–860.
- Yousem DM. Imaging of sinonasal inflammatory disease. *Radiology.* 1993;188(2):303–314.
- Fatterpekar G, Delman B, Som P. Imaging the paranasal sinuses: where we are and where we are going. *Anat Rec.* 2008;291(11):1564–1572.
- Islam T, Al-Azad S, Khondker L, Akhter S. CT evaluation of malignant paranasal sinus mass and histopathological correlation. *BSMMU J.* 2013;6(1):33–37.
- Miller JC. Imaging for sinusitis. *Radiology Rounds.* Massachusetts General Hospital Department of Radiology. 2009;7(8):1–4.
- Momeni AK, Roberts CC, Chew FS. Imaging of chronic and exotic sinonasal disease: review. *AJR Am J Roentgenol.* 2007;189:S35–S45.
- Spector SL, Bernstein IL, Li JT, et al. Parameters for the diagnosis and management of sinusitis. *J Allergy Clin Immunol.* 1998;102(6 Pt 2):S107–S144.
- Gotwald TF, Zinreich SJ, Corl F, Fishman EK. Three-dimensional volumetric display of the nasal ostiomeatal channels and paranasal sinuses. *AJR Am J Roentgenol.* 2001;176(1):241–245.
- Chaitanya CS, et al. Computed tomographic evaluation of diseases of paranasal sinuses. *Int J Recent Sci Res.* 2015;6(7):5081–5086.
- Surapaneni H, Sisodia SS. Aetiology, diagnosis and treatment of chronic rhinosinusitis: a study in a teaching hospital in Telangana. *Int J Otorhinolaryngol Head Neck Surg.* 2016;2:14–17.
- Nepal A, Chettri ST, Joshi RR, Karki S. Benign sinonasal masses: a clinicopathological and radiological profile. *Kathmandu Univ Med J.* 2013;41(1):4–8.
- Kanwar SS, Mital M, Gupta PK, Saran S, Parashar N, Singh A. Evaluation of paranasal sinus diseases by computed tomography and its histopathological correlation. *J Oral Maxillofac Radiol.* 2017;5:46–52.
- Kawaguchi M, Kato H, Tomita H, Mizuta K, Aoki M, Hara A, Matsuo M. Imaging characteristics of malignant sinonasal tumour. *J Clin Med.* 2017;6(12):102–116.
- Heidi B. Imaging of sinonasal tumours. *Cancer Imaging.* 2012;12:136–152.
- Bist S, Kusum A, Varshney S. Clinico-pathological profile of sinonasal masses: experience in a tertiary care hospital of Uttarakhand. *Natl J Maxillofac Surg.* 2012;3(2):180–185.
- Dean KE, Shatzkes D, Phillips CD. Imaging review of new and emerging sinonasal tumors and tumor-like entities from the fourth edition of the World Health Organization classification of head and neck tumors. *American Journal of Neuroradiology.* 2019 Apr 1;40(4):584–90.
- Zinreich SJ, Kennedy DV, Malat J. Fungal sinusitis: diagnosis with CT and MR imaging. *Radiology.* 1988;169(2):439–444.