

# Aesthetic & Functional Outcome following Ventral Hernioplasty & Lipo-abdominoplasty in Bangladesh

DOI: 10.5281/zenodo.17236532

Muhammed Shariful Islam<sup>1</sup>, Talukder AGM Zakaria Nazimuddin Jubery<sup>2</sup>

Received: 07 Aug 2025

Accepted: 12 Aug 2025

Published: 27 Aug 2025

**Published by:**

Gopalganj Medical College, Gopalganj, Bangladesh

**Correspondence to**

Muhammed Shariful Islam

**ORCID**<https://orcid.org/0009-0005-3565-3102>

Copyright © 2025 The Insight

This article is licensed under a [Creative Commons Attribution 4.0 International License](https://creativecommons.org/licenses/by/4.0/).**ABSTRACT**

**Background:** Ventral hernias, often associated with abdominal wall weakness and previous surgeries, pose both functional and aesthetic challenges. Lipo-abdominoplasty has emerged as a complementary approach that addresses contour deformities while reinforcing the abdominal wall. Aim of this study was to assess the aesthetic and functional outcome following Ventral Hernioplasty & Lipo-abdominoplasty in Bangladesh. **Methods & Materials:** This prospective observational study was conducted at Department of Plastic Surgery, Shaheed Ziaur Rahman Medical College Hospital, Bogura, Cosmetic Surgery Centre and Eden MultiCare Hospital, Dhaka, Bangladesh, from January 2021 to December 2021. Total 30 patients who underwent combined ventral hernioplasty and lipo-abdominoplasty during the study period were included in this study. **Result:** The majority of patients (90%) were female, with a mean age of 35.5 years ( $SD \pm 9.5$  years) and a mean BMI of  $24.7 \pm 2.9$  kg/m<sup>2</sup>. Most procedures were completed in under three hours with minimal intraoperative blood loss in 73.3% of cases. Hospital stay was  $\leq 3$  days in 83.3% of patients. Incisional hernias were most common (53.3%), and the onlay mesh technique was used in all patients. Functionally, 80% resumed daily activities by day 7, and 70% returned to work within two weeks. Early complications were observed in 30% of cases, with seroma being the most common (16.7%). **Conclusion:** Combined ventral hernioplasty and lipo-abdominoplasty offers a safe and effective solution with favorable functional recovery, minimal complications, and enhanced abdominal aesthetics. This integrated surgical approach is particularly relevant for middle-aged, comorbid female patients and shows promising potential in resource-constrained surgical settings like Bangladesh.

**Keywords:** Aesthetic Outcome, Functional Outcome, Ventral Hernioplasty, and Lipo-abdominoplasty.

(The Insight 2025; 8(1): 9-14)

1. Registrar, Department of Plastic Surgery, National Institute of Burn & Plastic Surgery, Dhaka, Bangladesh
2. Assistant Professor, Department of Plastic Surgery, Dhaka Medical College, Dhaka, Bangladesh

**INTRODUCTION**

Ventral hernias impose a considerable global surgical load, particularly following twin pregnancy and laparotomies, with rates of up to 20% in some postoperative groups<sup>[1]</sup>. They develop under the impact of a multifactorial risk factor profile that includes obesity, prior abdominal surgery, wound dehiscence, smoking, and impaired nutritional or tissue healing status<sup>[2,3]</sup>. The incidence is particularly high in the South Asian countries, with increasing cesarean section rates and increasingly open abdominal surgeries being some of the factors in the rising incidence of hernias<sup>[4]</sup>. Despite these rising figures, there is a dearth of large-scale epidemiological and surgical outcome studies from South Asia, particularly Bangladesh. Reports of patient-centered outcomes like postoperative function and aesthetic satisfaction are even

scarcer, demonstrating a significant gap in both surgical literature and health policy relevant to this region of the world<sup>[1]</sup>.

The surgical management of ventral hernias has undergone a dramatic transformation over the last several decades. Having previously been managed with primary suture repair, these methods have been found to carry high recurrence rates greater than 40% in some series especially in patients with larger defects or risk-filled profiles<sup>[5]</sup>. This has led to the universal application of mesh-based methods, which reduce recurrence and improve abdominal wall integrity significantly. There occurred along with this progression the development of anatomical placement methods like onlay mesh placement, which intended to eliminate complications such as seromas, infection, and mesh migration<sup>[6]</sup>. Component

separation techniques, such as posterior and endoscopic, facilitated tension-free closure in large or complex hernias, with the possibility of improved long-term durability<sup>[7]</sup>. These developments not only enhance structural repair but have also paved the way for the integration of reconstructive and aesthetic procedures in abdominal wall surgery.

One such development is lipo-abdominoplasty, a refinement of the traditional abdominoplasty. Designed to preserve neurovascular structures and reduce flap necrosis, it combines deep-plane liposuction with skin resection and myofascial plication to provide both cosmetic enhancement and core stabilization<sup>[8]</sup>. Over the past decade, the combined ventral hernia repair and lipo-abdominoplasty has become increasingly popular. This combination provides the unique benefits of a single anesthetic exposure, a consolidated recovery, and the twofold advantage of functional reconstruction and aesthetic contouring<sup>[9]</sup>. This synergy is particularly applicable in women who have postnatal or post-weight loss abdominal wall deformity, where both functional disability and psychosocial distress are present. While Western literature has demonstrated low complication rates and high patient satisfaction with said combined procedures, there remains an acute lack of data replicating their performance in South Asia or low-resource settings.

Bangladesh, with its rapidly urbanizing healthcare system, provides a compelling background for considering this surgical symbiosis. Nonetheless, there is a significant gap in outcome-based surgical studies in recording the unique regional idiosyncrasies. These include heterogeneous surgeon experience in aesthetic and reconstructive surgeries, delayed presentations due to sociocultural stigma, and underreporting of body image concerns, especially in postnatal women where abdominal deformity is normalized or tacitly accepted<sup>[2]</sup>. Also, societal expectations often prompt women to prioritize family duties over personal reconstruction, once more resulting in further care delay or compromise.

In view of this imbalance, the present study was designed as a prospective observational study to assess both aesthetic and functional outcomes following concomitant ventral hernioplasty and lipo-abdominoplasty in a Bangladeshi tertiary care setting

**OBJECTIVES**

To assess the aesthetic and functional outcome following Ventral Hernioplasty & Lipo-abdominoplasty in Bangladesh.

**METHODS & MATERIALS**

This prospective observational study was conducted at Department of Plastic Surgery, Shaheed Ziaur Rahman Medical College Hospital, Bogura, Cosmetic Surgery Centre and Eden MultiCare Hospital, Dhaka, Bangladesh, from January 2021 to December 2021. Total 30 patients who underwent combined ventral hernioplasty and lipo-abdominoplasty during the study period were included in this study. Patients were selected based on pre-defined inclusion criteria, which required candidates to be adult individuals (aged 30–50 years) presenting with a diagnosed ventral hernia and an indication for abdominoplasty, either due to

excess abdominal skin, muscular laxity, or post-weight loss body contour deformity. Patients with recurrent hernias, major comorbidities contraindicating elective surgery, or those unwilling to participate in follow-up evaluations were excluded. Preoperative assessments included detailed medical history, physical examination, and imaging studies where necessary. Surgical planning involved a multidisciplinary approach with preoperative counseling covering both the functional and aesthetic goals of the procedure. All operations were performed under spinal anesthesia by a dedicated plastic surgical team trained in abdominal wall reconstruction and aesthetic body contouring techniques. Standardized protocols were followed for mesh selection, mesh placement, and flap design for abdominoplasty. Postoperative care protocols were unified across both centers and included analgesia, early ambulation, and use of compression garments. Patients were monitored for complications such as wound dehiscence, seroma, infection, and hernia recurrence. Functional outcomes were evaluated based on pain resolution, core stability, and physical activity tolerance, while aesthetic outcomes were assessed through clinical scoring and patient-reported satisfaction. Follow-up assessments were carried out at 1, 3, and 6 months postoperatively. Ethical approval for the study was obtained from the institutional ethical review board prior to commencement. Written informed consent was taken from all of the participants. All collected data were recorded systematically and analysed using SPSS software version 26.

**RESULT**

**Table – I: Baseline characteristics of the study patients (n=30)**

Characteristics	Number of Patients	Percentage (%)
<b>Age Group (Years)</b>		
18-24	8	26.7
25-34	9	30
35-44	8	26.7
≥45	5	16.6
Mean ± SD	35.5 ± 9.5	
Range	30-50	
<b>Sex</b>		
Male	3	10
Female	27	90
<b>BMI (kg/m<sup>2</sup>)</b>		
Mean ± SD	24.7 ± 2.9	
<b>Comorbidities</b>		
None	14	46.7
Diabetes	9	30.0
Hypertension	7	23.3

Table I presents the baseline characteristics of the 30 patients enrolled in this study. The majority of patients (30%) were in the 25–34-year age group, followed by 26.7% each in the 18–24 and 35–44 age groups, and 16.6% were aged ≥45 years. The mean age of the study population was 35.5 years (SD± 9.5 years). Regarding sex distribution, female patients dominated the sample, comprising 90% (n=27), while males represented

10% (n=3). The mean body mass index (BMI) was  $24.7 \pm 2.9$  kg/m<sup>2</sup>. With regard to comorbidities, nearly half the patients (46.7%) reported no comorbid conditions, while 30% had

diabetes and 23.3% had hypertension, reflecting common metabolic risk factors that may influence surgical outcomes.

**Table - II: Surgical outcome of the study patients (n=30)**

Surgical Outcome Variable		Frequency (n)	Percentage (%)
Duration of Surgery	< 3 hours	19	63.3
	≥ 3 hours	11	36.7
Intraoperative Blood Loss	Minimal (<250 ml)	22	73.3
	Moderate (250–500 ml)	8	26.7
Surgical Site Drain Placement	Required	26	86.7
	Not required	4	13.3
Hospital Stay	≤ 3 days	25	83.3
	> 3 days	5	16.7

Table II outlines the surgical outcomes among the study population. In terms of operative duration, 63.3% of the procedures were completed in under 3 hours, while 36.7% lasted 3 hours or more, depending on complexity and the extent of combined procedures. Intraoperative blood loss was minimal (<250 ml) in 73.3% of cases, and moderate in 26.7%, indicating a largely controlled surgical field. A surgical drain was placed in 86.7% of patients, while 13.3% did not require it. Regarding hospital stay, the majority of patients (83.3%) were discharged within three days, while only 16.7% required prolonged admission, highlighting favorable early postoperative recovery in most cases.

**Table - III: Type of hernia and position of mesh among the study patients (n=30)**

Category	Number of Patients	Percentage (%)
<b>Hernia Type</b>		
Umbilical	14	46.7
Incisional	16	53.3
<b>Mesh Position</b>		
Onlay	30	100

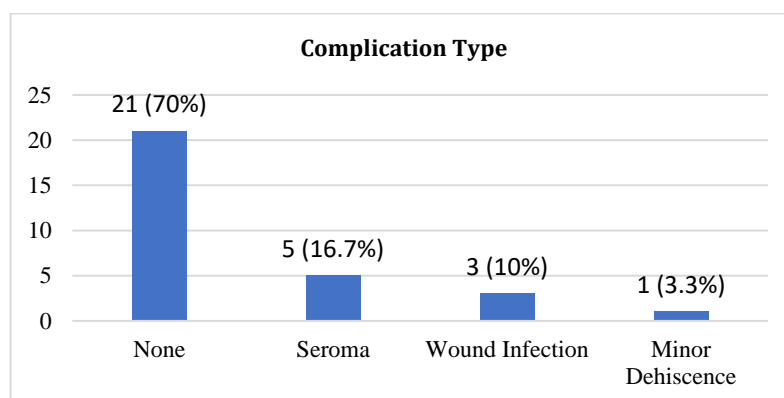
Table III categorizes patients by hernia type and mesh placement technique. Among the types of ventral hernias encountered, incisional hernias were the most common

(53.3%), followed by umbilical (46.7%). Regarding mesh positioning, onlay method was used in all patients.

**Table - IV: Functional outcome of the study patients (n=30)**

Functional outcome	Number of Patients	Percentage (%)
Able to resume daily activity by Day 7	24	80
No core pain during basic activities	26	86.7
Improved posture/core stability reported	23	76.7
Returned to work within 2 weeks	21	70

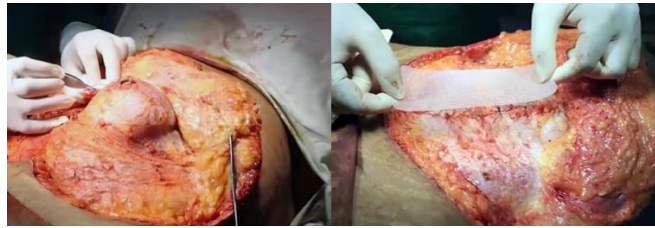Table IV details the functional outcomes observed in the early postoperative period. Notably, 80% of patients resumed their daily activities by postoperative day 7, suggesting a rapid recovery trajectory. In terms of discomfort, 86.7% reported no core pain during basic activities, indicating effective structural reinforcement. Furthermore, 76.7% of patients reported improved posture and core stability, aligning with the goals of combining ventral hernia repair with rectus-muscle plication during lipo-abdominoplasty. Additionally, 70% of patients returned to work within two weeks, affirming the functional success and quality-of-life impact of the procedure.



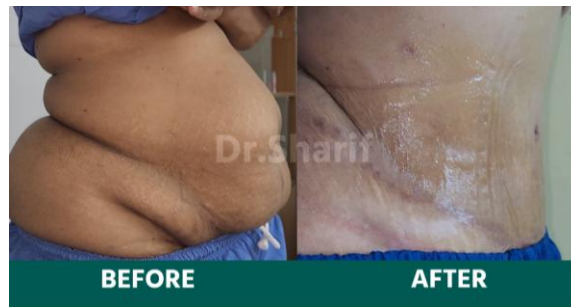**Figure - 1: Distribution of complications among the study patients (n=30)**

Figure 1 presents the distribution of early postoperative complications observed in the study population. Of the 30 patients assessed, the majority (70%) experienced no complications, underscoring the relative safety and tolerability of the combined ventral hernioplasty and lipo-abdominoplasty procedure. Among those who did develop complications, seroma formation was the

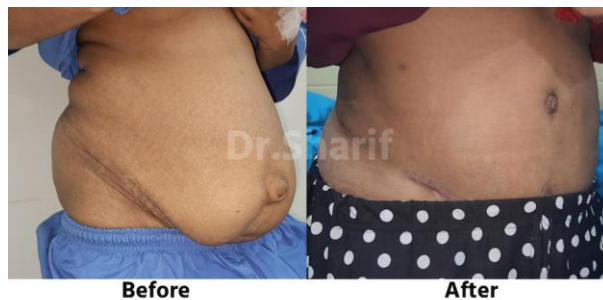most common, occurring in 5 patients (16.7%), which is consistent with expected outcomes in abdominoplasty-based surgeries involving large tissue planes. Wound infection was noted in 3 patients (10%), all of which were managed conservatively without requiring reoperation. A single case (3.3%) of minor wound dehiscence was reported, also resolving with routine wound care.



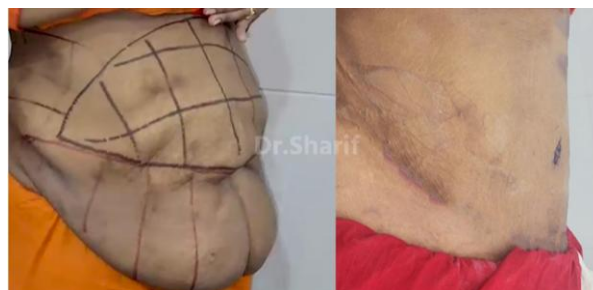**Figure - 2: Dissection and exposure of hernial sac and intraoperative placement of polypropylene mesh over the abdominal wall during hernioplasty**



**Figure - 3: Preoperative and postoperative comparison following ventral hernioplasty with lipo-abdominoplasty on a female patient**



**Figure - 4: Dramatic contour improvement and umbilical realignment post lipo-abdominoplasty with ventral hernia repair**



**Figure - 5: Preoperative marking and final result after 360° lipo-abdominoplasty with ventral hernia repair**

**DISCUSSION**

The present study aimed to assess the aesthetic and functional outcomes of combined ventral hernioplasty and lipo-abdominoplasty, with a particular focus on patient recovery,

complication rates, and quality-of-life improvements. The demographic profile of the cohort demonstrated that the majority of patients were middle-aged females, with a mean age of 35.5 years. This aligns with earlier studies reporting

similar trends, where female individuals represent a large proportion of those seeking abdominal wall reconstruction, often due to post-pregnancy laxity or prior surgeries<sup>[10,11]</sup>. Interestingly, the majority of patients in this study presented with a normal BMI (mean 24.7 kg/m<sup>2</sup>), challenging the prevailing assumption that body contouring and hernia repairs are exclusive to obese or overweight individuals. Previous studies corroborate this finding, illustrating that normal-weight patients often pursue abdominoplasty for functional or aesthetic reasons unrelated to obesity<sup>[12,13]</sup>. Additionally, Plehutsa et al.<sup>[14]</sup> identified a subgroup of abdominoplasty patients with normal BMIs undergoing surgery for abdominal wall defects, further validating our patient profile. The prevalence of comorbidities, particularly diabetes (30%) and hypertension (23.3%), also mirrors global findings, confirming the metabolic overlap that contributes to increased surgical candidacy and potential risks<sup>[15]</sup>. Operative data revealed that most procedures were completed in under three hours, with intraoperative blood loss remaining minimal in 73.3% of cases, which is consistent with findings from Eltantawy et al.<sup>[16]</sup>, who observed similar trends in hernio-abdominoplasty with Scarpa's fascia preservation. The high rate of drain placement observed (86.7%) is consistent with standard practices in abdominoplasty procedures where seroma prevention is critical. In high-volume centers with access to progressive tension sutures, the use of drains remains prevalent in many surgical settings, particularly where resource constraints or patient risk profiles justify it.<sup>[9,17]</sup> These practices also align with the reported use of multiple suprafascial drains in complex abdominal wall reconstructions.<sup>[18]</sup> The majority of patients (83.3%) were discharged within three days, a favorable early postoperative course that compares well with previous large-scale studies on combined procedures reporting mean hospital stays of 2-4 days<sup>[19,20]</sup>.

Regarding hernia types, incisional hernias were the most common (53.3%), followed by umbilical (46.7%), aligning closely with global epidemiological data<sup>[21]</sup>. Regarding mesh positioning, onlay method was used in all patients.

Functionally, outcomes were encouraging. A large majority (80%) resumed daily activities by Day 7, and 86.7% reported no core pain during basic movements, indicating robust early recovery. These findings are comparable to those by Licari et al.<sup>[22]</sup>, who demonstrated measurable improvement in core stability and quality-of-life parameters following incisional hernia repair. Notably, 76.7% of our patients reported postural and core stability improvement, consistent with Mazzocchi et al.<sup>[18]</sup>, who documented postural enhancements following rectus plication. Additionally, 70% returned to work within two weeks, paralleling the return-to-function timeline described by Adams et al.<sup>[23]</sup> and Swedenhammar<sup>[24]</sup>.

The overall complication rate was 30%, with seroma being the most frequent (16.7%), followed by wound infection (10%) and minor dehiscence (3.3%). These figures fall within the range reported in previous literature. Jabaiti<sup>[25]</sup> and Vidal et al.<sup>[26]</sup> both reported seroma rates of approximately 15–20% following abdominoplasty-based procedures, particularly when combined with liposuction or extensive undermining.

Wound infections in our cohort were conservatively managed and align with Massey et al.<sup>[27]</sup>, who emphasized that most seromas and superficial infections resolve without surgical reintervention. The isolated case of minor wound dehiscence (3.3%) also supports findings by Denys et al.<sup>[28]</sup>, suggesting that such complications, while notable, do not significantly compromise outcomes when managed appropriately.

The outcomes of this study affirm the growing international consensus that combining ventral hernioplasty with lipo-abdominoplasty offers both functional reinforcement and aesthetic improvement with a favorable safety profile. The demographic similarities, operative feasibility, complication rates, and functional recovery observed in this cohort resonate with global literature, supporting its relevance and reproducibility in low-resource, high-volume surgical environments like Bangladesh.

### Limitations of the study

In our study, there was small sample size and absence of control for comparison. The study was conducted at a short period of time.

### CONCLUSION AND RECOMMENDATIONS

This study demonstrates that combined ventral hernioplasty and lipo-abdominoplasty is a safe and effective surgical approach, offering both functional and aesthetic benefits. With minimal complications, early recovery, and high patient satisfaction, it presents a viable solution for abdominal wall reconstruction in resource-limited settings like Bangladesh. The predominance of favorable outcomes underscores the value of integrated surgical planning. Further multicentric, long-term studies are warranted to validate these findings and guide standardized protocols for combined reconstructive procedures.

### REFERENCES

- Zhang J, Wang J, Han X, Fan J, Huang C, Dong Y. Global burden and future trends of inguinal, femoral, and abdominal hernia in older adults: A systematic analysis from the Global Burden of Disease Study 2021. *PLoS One*. 2025;20(4):e0323790.
- Ahsan MM, Afroz T, Kabir ME. A prospective observational study of clinical profile of patients with ventral hernia. *SAS J Surg*. 2024;10(10):1124–7.
- Raza VF, Chohan MS, Nazir A. Factors associated with development of ventral hernias and healthcare seeking behaviors in a cohort of Pakistani women. *Pak J Med Health Sci*. 2022;16(5):110–4.
- Satapathy P, Jena A, Gaidhane AM, Vadia N. Burden of inguinal, femoral, and abdominal hernias in India: A systematic analysis of prevalence, incidence, mortality, and DALYs from Global Burden of Disease Study. *Hernia*. 2025.
- Petrie K, Cox CT, Becker BC. Clinical applications of acellular dermal matrices: A review. *Scars Burns Heal*. 2022;8:1–8.
- Cohen M, Zaluzec RM. Reconstruction chapter 12 of abdominal wall defects after bariatric surgery and simultaneous abdominal lipectomies. In: *Plastic Surgery: Volume 6: Trunk and Lower Extremity*. 2013. p. 113–28.
- Rangaswamy M. Minimising complications in abdominoplasty: An approach based on the root cause analysis and focused preventive steps. *Indian J Plast Surg*. 2013;46(2):365–72.

8. Mendes F, Viterbo F. Abdominoplasty after massive weight loss. In: *Aesthetic Plastic Surgery in Asians*. Springer; 2016. p. 233–41.
9. Klemm LE. *Postoperative complications of abdominoplasty: Etiology, risk factors, diagnostics, treatment options and methods of prevention [dissertation]*. Vilnius University; 2025. VU ePublications.
10. Owei L, Ifabiyi A, Choudhury N. Impact of body mass index on open ventral hernia repair outcomes. *Surgery*. 2017;161(6):1660–6.
11. Baig MM, Priya R. Ventral hernias in high BMI patients: A regional experience. *Hernia*. 2021;25:447–53.
12. Cuomo R, Cuccaro C, Seth I, Rozen WM. Experience in post-bariatric abdominoplasty for patients with significant weight loss: a prospective study. *J Pers Med*. 2024;14(7):681.
13. Hoyos A, Perez ME, Guarin DE. A report of 736 high-definition lipoabdominoplasties performed in conjunction with circumferential VASER liposuction. *Plast Reconstr Surg*. 2018 Sep.
14. Plehutsa OI, Kalashnikov OO, Hrynevych AA. Features of the morbid background of patients with defects and aesthetic deformities of the anterior abdominal wall. 2025.
15. Ferguson M, Stevens M, Ramirez T. Outcomes after hernia repair in comorbid patients: A national database analysis. *J Surg Res*. 2021;267:219–25.
16. Eltantawy A, El-Marakby H, El-Anwar M. Hernio-abdominoplasty with or without Scarpa's fascia preservation: A comparative study. *Plast Reconstr Surg Glob Open*. 2019;7(7):e2345.
17. Shauly O, Goel P, Gould DJ. Painless, drainless lipoabdominoplasty: a retrospective study of pain following lipoabdominoplasty utilizing liposomal bupivacaine and a modified enhanced recovery after surgery protocol. In *Aesthetic Surgery Journal Open Forum 2022 Jan 1 (Vol. 4, p. ojac049)*. US: Oxford University Press.
18. Mazzocchi M, Onesti MG, Spalvieri C. A study of postural changes after abdominoplasty. *Hernia*. 2014;18(1):137–43.
19. Cheesborough JE, Dumanian GA. Simultaneous prosthetic mesh abdominal wall reconstruction with abdominoplasty. *Plast Reconstr Surg*. 2015;135(1):268–76.
20. McNichols CH, Bauer JJ, Gaughan JP. Outcomes of ventral hernia repair with concomitant panniculectomy. *Ann Plast Surg*. 2018;80(4):350–5.
21. Dhaigude R, Shekhawat NS, Wagh AD. Comparative evaluation of sublay versus onlay meshplasty in incisional and ventral hernias. *Int Surg J*. 2017;4(1):76–80.
22. Licari L, Benassai G, De Palma M. Clinical and functional outcome after abdominal wall incisional hernia repair: Evaluation of quality-of-life improvement. *Updates Surg*. 2019;71:97–102.
23. Adams AK, Guest JF, Reeves BC. Physical activity and return to function after abdominal wall reconstruction: A scoping review. *Hernia*. 2022;26(2):301–13.
24. Swedenhammar E. *Observations on diagnostic reliability and the surgical treatment of abdominal rectus diastasis [dissertation]*. Karolinska Institutet; 2024. Karolinska Open Archive.
25. Jabaiti SK. Complications of abdominoplasty: How to prevent and manage them. *Plast Aesthet Res*. 2009;5(2):85–92.
26. Vidal P, Berner JE, Will JW. Complications after abdominoplasty: A review. *Arch Plast Surg*. 2017;44(5):457–68.
27. Massey L, Graham M, Stewart P. Reducing seroma formation after incisional hernia repair: A review of adjunct techniques. *Hernia*. 2018;22(4):685–92.
28. Denys A, Grossi J, Claus C. Wound dehiscence after abdominal wall reconstruction: A systematic review. *Hernia*. 2021;25(5):1157–65.