Open Access

ISSN: 2663-9491 e-ISSN: 2789-6897

ORIGINAL ARTICLE

Diagnostic Utility of Serum CA 19-9 in Differentiating Benign and Malignant Pancreatic Lesions

Sharif Mushfaqur Rahman[1], Nur Hossain Shaheen[2], Probir Kumar Sutradhar[3], Nazrul Islam[4], Ridwan Tareen[5], Shah Alom[6], S M Sarwar[7]

Received: 15 November 2026
Accepted: 21 November 2026
Published Online: 23 November 2026

Published by:
Gopalganj Medical College, Gopalganj, Bangladesh

*Corresponding Author

DOI: 10.5281/zenodo.24475123

Copyright © 2026 The Insight

This article is licensed under a Creative Commons Attribution 4.0 International License.s

ABSTRACT

Background: *Because pancreatic lesions include both benign and malignant conditions with overlapping clinical and imaging features, accurate differentiation remains challenging, particularly in settings with limited access to advanced diagnostic facilities. Among available biomarkers, serum CA 19-9 is widely used for pancreatic malignancy, although false-positive elevation in benign pancreatobiliary disease and false-negative results may limit its standalone utility.* ***Aim of the study:*** *This study aimed to evaluate the diagnostic utility of serum CA 19-9 in differentiating benign from malignant pancreatic lesions.* ***Methods & Materials:*** *In this hospital-based cross-sectional diagnostic accuracy study, 135 adult patients with pancreatic lesions attending the Department of Surgery, Cox's Bazar Medical College, Cox's Bazar, Bangladesh were enrolled consecutively from January 2025 to December 2025. Serum CA 19-9 was measured before definitive treatment, with >37 U/mL considered elevated. Based on histopathology, cytology, or compatible clinical and imaging findings, lesions were classified as benign or malignant. Using SPSS version 27.0, diagnostic performance was assessed by sensitivity, specificity, predictive values, accuracy, and ROC analysis; p<0.05 was considered statistically significant.* ***Results:*** *Among 135 patients, 81 (60.0%) had malignant and 54 (40.0%) had benign pancreatic lesions. Compared with benign lesions, malignant lesions showed significantly higher median CA 19-9 levels, 236 versus 27 U/mL, p<0.001, and more frequent CA 19-9 elevation >37 U/mL: 77.8% versus 18.5%. At >37 U/mL, CA 19-9 demonstrated 77.8% sensitivity, 81.5% specificity, 86.3% PPV, 71.0% NPV, and 79.3% accuracy. On ROC analysis, good discrimination was observed, with an AUC of 0.846; an optimal cut-off of 82 U/mL yielded 76.5% sensitivity and 85.2% specificity.* ***Conclusion:*** *Overall, serum CA 19-9 showed good diagnostic performance in differentiating malignant from benign pancreatic lesions. However, because false-positive elevations may occur in benign conditions, CA 19-9 should be interpreted together with clinical assessment, imaging, and histopathological or cytological findings rather than used as a standalone diagnostic test.*

Keywords: *CA 19-9; Pancreatic lesions; Pancreatic malignancy; Diagnostic accuracy*

(The Insight 2026; 9(3): 1138-1143)

1. *Assistant Professor, Department of Surgery, Cox's Bazar Medical College, Cox's Bazar, Bangladesh (ORCID: 0009-0007-5692-8835)*
2. *Professor & Head, Department of Surgery, Cox's Bazar Medical College, Cox's Bazar, Bangladesh*
3. *Assistant Professor, Department of Surgery, Cox's Bazar Medical College, Cox's Bazar, Bangladesh*
4. *Associate Professor, Department of Surgery, Cox's Bazar Medical College, Cox's Bazar, Bangladesh*
5. *Resident Surgeon, Department of Surgery, 250-Bed Sadar Hospital, Cox's Bazar, Bangladesh*
6. *Associate Professor, Department of Surgery, Cox's Bazar Medical College, Cox's Bazar, Bangladesh*
7. *Assistance Professor, Department of Surgery, Cox's Bazar Medical College, Cox's Bazar, Bangladesh*

INTRODUCTION

Pancreatic lesions encompass a heterogeneous spectrum of inflammatory, cystic, premalignant, and malignant disorders, and distinguishing benign from malignant lesions remains an important diagnostic challenge. Clinically, pancreatic ductal adenocarcinoma represents the dominant malignant pancreatic neoplasm and is characterized by aggressive biological behavior, late presentation, and limited opportunities for curative treatment [1-3]. Because early symptoms are frequently nonspecific, many patients present only after the development of jaundice, weight loss, abdominal pain, vascular involvement, or metastatic disease [3,4]. Consequently, an accurate and relatively non-invasive method for differentiating malignant from benign pancreatic lesions may facilitate appropriate investigation, referral, biopsy, and treatment planning. Globally, pancreatic cancer represents a relatively smaller proportion of all cancers but contributes disproportionately to cancer mortality. According to recent GLOBOCAN estimates, approximately 531,000 new pancreatic cancer cases and 491,000 deaths occurred worldwide in 2024, making pancreatic cancer the sixth leading cause of cancer death [1]. Over recent decades, an increasing global burden has also been demonstrated, with approximately 508,533 incident cases reported in 2021 and rising age-standardized incidence rates since 1990 [2]. Although incidence is substantially lower in South Asia than in many high-income regions, diagnostic limitations and restricted access to specialized pancreatic imaging, endoscopic procedures, pathology, and oncological services may complicate timely diagnosis [2]. Within Bangladesh, evidence remains limited; however, a study

ISSN: 2663-9491 e-ISSN: 2789-6897

conducted in Dhaka demonstrated that pancreatic masses are frequently malignant and emphasized the diagnostic importance of imaging with histopathological confirmation [5]. Among available serum biomarkers, carbohydrate antigen (19-9, CA 19-9) remains the most extensively used marker in the clinical evaluation of pancreatic malignancy [6,7]. Biologically, CA 19-9 is a sialylated Lewis's antigen expressed by pancreatic and biliary epithelial cells, and serum concentrations may increase considerably in pancreatic adenocarcinoma [6]. Meta-analytic evidence has demonstrated approximately 80% sensitivity and 75% specificity, with an area under the receiver operating characteristic curve of approximately 0.84 for pancreatic cancer diagnosis [7]. More recent analyses have similarly demonstrated useful discriminatory performance of CA 19-9 when pancreatic malignancy is compared with benign disease, although its diagnostic accuracy remains insufficient for use as a stand-alone test [8,9]. Importantly, several factors limit the specificity and sensitivity of CA 19-9. In benign pancreatobiliary disorders, particularly obstructive jaundice, cholangitis, and inflammatory disease, substantial elevations may occur and produce false-positive results [10]. Conversely, low or undetectable CA 19-9 levels may occur in individuals with a Lewis-antigen-negative phenotype, even in the presence of pancreatic malignancy [11]. Therefore, interpretation requires integration with clinical findings and imaging modalities such as contrast-enhanced computed tomography, magnetic resonance imaging, and endoscopic ultrasonography [4,12]. Within Bangladesh, locally generated evidence concerning the diagnostic performance of CA 19-9 remains particularly limited. A recent study from Dhaka Medical College demonstrated the clinical usefulness of preoperative CA 19-9 in pancreatic malignancy, but focused primarily on predicting tumor resectability rather than differentiating benign from malignant pancreatic lesions [13]. Consequently, evaluation of sensitivity, specificity, predictive values, diagnostic accuracy, and an optimal CA 19-9 threshold in a local patient population remains clinically relevant. Therefore, the present study aimed to evaluate the diagnostic utility of serum CA 19-9 in differentiating benign from malignant pancreatic lesions and to determine its diagnostic performance using receiver operating characteristic analysis.

METHODS & MATERIALS

This hospital-based cross-sectional diagnostic accuracy study was conducted in the Department of Surgery, Cox's Bazar Medical College, Cox's Bazar, Bangladesh, among patients evaluated for pancreatic lesions. During the study period, from January 2025 to December 2025, 135 consecutive eligible patients were enrolled using a non-probability consecutive sampling technique. Based on the final diagnosis, 54 patients were classified as having benign pancreatic lesions and 81 as having malignant lesions. Eligibility criteria included adult patients aged ≥18 years with a pancreatic lesion identified by ultrasonography, computed tomography, or magnetic resonance imaging. Patients with a previously treated pancreatic malignancy, known non-pancreatic malignancy associated with elevated CA 19-9, severe hepatic dysfunction, incomplete investigations, or unwillingness to participate were excluded. Before data collection, informed written consent was obtained from each participant, and ethical approval was obtained from the appropriate institutional review committee. Using a structured data collection form, demographic characteristics, presenting symptoms, diabetes status, and relevant clinical findings were recorded. Following standard imaging assessment, lesion size, anatomical location, solid or cystic morphology, pancreatic duct dilatation, biliary obstruction, and regional lymphadenopathy were documented. Before definitive treatment or intervention, venous blood was collected to measure serum carbohydrate antigen 19-9 (CA 19-9) using the laboratory's standardized immunoassay method. A CA 19-9 concentration of >37 U/mL was considered elevated for the primary diagnostic analysis. For establishing the reference diagnosis, histopathological or cytological findings from surgical specimens or image-guided/endoscopic biopsy were used whenever available. When tissue sampling was not clinically indicated for clearly benign lesions, the final diagnosis was established using compatible clinical, biochemical, imaging, and follow-up findings. Patients were subsequently categorized as having benign or malignant pancreatic lesions. Data was analyzed using SPSS (V. 27.0), continuous variables were summarized as mean ± standard deviation or median with interquartile range, according to data distribution, while categorical variables were expressed as frequency and percentage. Between-group comparisons were performed using the independent-samples t-test or Mann–Whitney U test for continuous variables and the chi-square or Fisher's exact test for categorical variables. Diagnostic performance at CA 19-9 >37 U/mL was assessed using sensitivity, specificity, positive predictive value, negative predictive value, and diagnostic accuracy with 95% confidence intervals. Finally, receiver operating characteristic analysis was performed to determine the area under the curve and identify the optimal CA 19-9 cut-off for differentiating malignant from benign pancreatic lesions. A p-value <0.05 was considered statistically significant.

RESULTS

Among the 135 participants, 54 had benign and 81 had malignant pancreatic lesions. Patients with malignant lesions were significantly older than those with benign lesions (60.2 ± 10.9 vs 49.1 ± 12.7 years; p<0.001). Jaundice (66.7% vs 33.3%) and weight loss (75.3% vs 25.9%) were also significantly more frequent in malignant lesions (both p<0.001). No significant differences were observed for sex, abdominal pain, or diabetes mellitus (*Table I*).

Table I
Baseline and clinical characteristics according to final diagnosis.

Variables		Benign (n=54)	Malignant (n=81)	p-value
		n (%) / Mean ± SD		
Age (years)		49.1 ± 12.7	60.2 ± 10.9	<0.001
Sex	Male	34 (63.0%)	52 (64.2%)	0.884
	Female	20 (37.0%)	29 (35.8%)	
Abdominal pain		44 (81.5%)	59 (72.8%)	0.247
Jaundice		18 (33.3%)	54 (66.7%)	<0.001
Weight loss		14 (25.9%)	61 (75.3%)	<0.001
Diabetes mellitus		14 (25.9%)	34 (42.0%)	0.056

ISSN: 2663-9491 e-ISSN: 2789-6897

Regarding imaging findings, malignant lesions were significantly larger than benign lesions (4.3 ± 1.6 vs 3.0 ± 1.3 cm, p<0.001). Solid morphology, pancreatic duct dilatation, biliary obstruction, and regional lymphadenopathy were substantially more common in malignant lesions (all p<0.001). Lesions ≥3 cm were also more frequent in the malignant group (76.5% vs 50.0%), while pancreatic-head location did not differ significantly (p=0.069) (*Table II*).

Table II
Major imaging characteristics of pancreatic lesions.

Variables	Benign (n=54)	Malignant (n=81)	p-value
	n (%) / Mean ± SD		
Lesion size (cm)	3.0 ± 1.3	4.3 ± 1.6	<0.001
Lesion ≥3 cm	27 (50.0%)	62 (76.5%)	0.001
Lesion in pancreatic head	29 (53.7%)	56 (69.1%)	0.069
Solid lesion	25 (46.3%)	71 (87.7%)	<0.001
Pancreatic duct dilatation	16 (29.6%)	53 (65.4%)	<0.001
Biliary obstruction	15 (27.8%)	50 (61.7%)	<0.001
Regional lymphadenopathy	4 (7.4%)	36 (44.4%)	<0.001

Serum CA 19-9 was markedly higher in malignant lesions than in benign lesions (median 236 U/mL, IQR 84–710 vs 27 U/mL, IQR 14–64; p<0.001). CA 19-9 levels >37 U/mL were present in 77.8% of malignant cases compared with 18.5% of benign cases. Similarly, levels >100 U/mL were observed in 70.4% versus 13.0%, respectively, both p<0.001 (*Table III*).

Table III
Serum CA 19-9 according to final diagnosis.

CA 19-9 parameter	Benign (n=54)	Malignant (n=81)	p-value
	n (%) / Median (IQR)		
CA 19-9 (U/mL)	27 (14–64)	236 (84–710)	<0.001
CA 19-9 >37 U/mL	10 (18.5%)	63 (77.8%)	<0.001
CA 19-9 >100 U/mL	7 (13.0%)	57 (70.4%)	<0.001

At a serum CA 19-9 cut-off of >37 U/mL, the test demonstrated a sensitivity of 77.8%, specificity of 81.5%, positive predictive value of 86.3%, and negative predictive value of 71.0% for detecting malignant pancreatic lesions. Overall diagnostic accuracy was 79.3%, indicating that serum CA 19-9 has useful discriminatory performance in differentiating malignant from benign pancreatic lesions (*Table IV*).

Table IV
Diagnostic performance of serum CA 19-9 at >37 U/mL.

Diagnostic measure	Value	95% CI
Sensitivity	77.80%	67.6–85.5
Specificity	81.50%	69.2–89.6
Positive predictive value (PPV)	86.30%	76.6–92.4
Negative predictive value (NPV)	71.00%	58.7–80.8
Diagnostic accuracy	79.30%	71.7–85.2

ISSN: 2663-9491 e-ISSN: 2789-6897

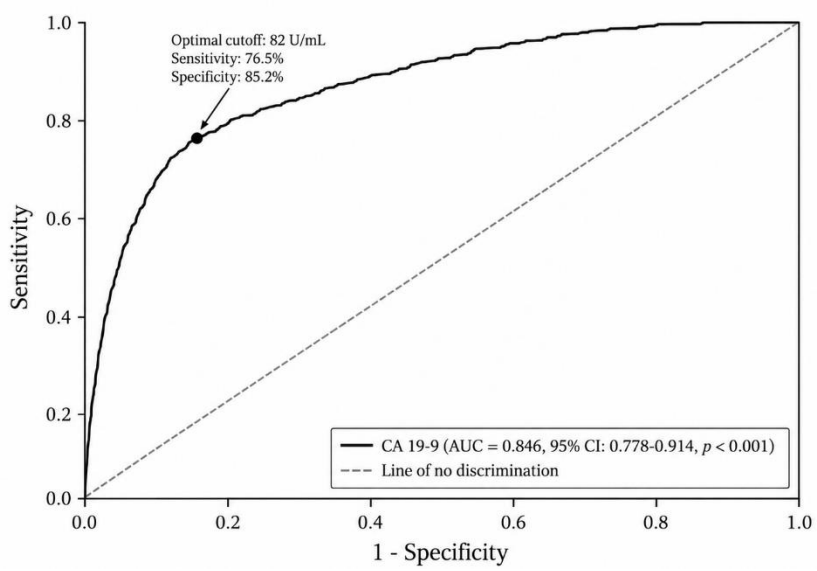

Figure 1: ROC curve showing the diagnostic ability of serum CA 19-9 to differentiate malignant from benign pancreatic lesions.

Based on ROC analysis, serum CA 19-9 showed good diagnostic discrimination, with an AUC of 0.846 (95% CI 0.778–0.914, p<0.001). An optimal cut-off of 82 U/mL provided a sensitivity of 76.5% and specificity of 85.2% for differentiating malignant from benign pancreatic lesions (*Figure 1*).

DISCUSSION

In the present study, 81 of 135 patients (60.0%) had malignant pancreatic lesions, while 54(40.0%) had benign lesions. Patients with malignant lesions were older than those with benign lesions 60.2 ± 10.9 versus 49.1 ± 12.7 years; jaundice (66.7%) and weight loss (75.3%) were also significantly more frequent. In Bangladesh, the study by Hossain et al. reported malignant lesions in 60.3% of patients with pancreatic masses, with most patients aged 56–75 years [5]. Such similarity may reflect tertiary-care referral patterns, where older patients with clinically suspicious lesions are more likely to undergo specialist evaluation. Regarding imaging, malignant lesions were significantly larger than benign lesions (4.3 ± 1.6 versus 3.0 ± 1.3 cm), and more frequently demonstrated solid morphology (87.7%), pancreatic duct dilatation (65.4%), biliary obstruction (61.7%), and regional lymphadenopathy (44.4%). In the Bangladeshi MDCT study, 63.8% of lesions involved the pancreatic head and 72.3% showed main pancreatic duct dilatation, predominantly among malignant lesions [5]. Similarly, the study by Grassia et al. reported that higher CA 19-9 was associated with correct diagnosis among patients with chronic pancreatitis and pancreatic masses, while EUS-FNB achieved 93% diagnostic accuracy [14]. These observations reinforce the importance of combining biochemical markers with imaging and tissue diagnosis. Most importantly, the median serum CA 19-9 level was substantially higher in malignant lesions, 236 U/mL, IQR 84–710, than in benign lesions, 27 U/mL, IQR 14–64, p<0.001. At >37 U/mL, CA 19-9 was elevated in 77.8% of malignant cases compared with 18.5% of benign cases. In a large meta-analysis involving 20,991 participants, pooled sensitivity, specificity, and AUC were 72%, 86%, and 0.8474, respectively [15]. Likewise, the meta-analysis by Yang et al. reported 71% sensitivity, 88% specificity, and an AUC of 0.8322 [16], while the study by Skulimowski et al. estimated sensitivity at 74.8% and specificity at 78.2% [17]. These results closely resemble the present sensitivity of 77.8%, specificity of 81.5%, and AUC of 0.846. Further evidence supports the moderate-to-good discriminatory ability of CA 19-9. In the meta-analysis by Cao et al., serum CA 19-9 differentiated benign from malignant pancreatic cystic neoplasms with 47% sensitivity, 88% specificity, and an AUC of 0.87 [18]. In another meta-analysis, CA 19-9 demonstrated greater sensitivity and AUC than CEA for pancreatic cancer diagnosis [7]. Similarly, the study by Okasha et al. reported 64.1% sensitivity and 68.1% specificity for cyst-fluid CA 19-9 at a cut-off of 1,318 U/mL [19]. Differences from the current findings may relate to cystic-only populations, specimen type, disease stage, and different diagnostic thresholds. At >37 U/mL, the present PPV was 86.3%, NPV 71.0%, and overall accuracy 79.3%. In early-detection research, the study by Fahrmann et al. reported 46% sensitivity at 99% specificity when respectable pancreatic cancer was compared with chronic pancreatitis and only 30% sensitivity against noncancerous pancreatic cysts [20]. Such lower sensitivity reflects the deliberately high specificity threshold and inclusion of diagnostically challenging benign controls. Conversely, the study by Mayerle et al. achieved an AUC of 0.94, sensitivity of 89.9%, and specificity of 91.3% by combining metabolites with CA 19-9 [21]. Likewise, the study by Zhang et al. achieved an AUC of 0.894, sensitivity of 73.8%, and specificity of 88.6% using MUC5AC plus CA 19-9 [22]. Importantly, false-positive CA 19-9 elevation remains a major limitation. In a 2024 meta-analysis of autoimmune pancreatitis, CA 19-9 was elevated in 49% of evaluated cases [23]. Earlier, the study by Yan et al. showed that combining CA 19-9 with globulin, eosinophils, and hemoglobin improved differentiation between autoimmune pancreatitis and pancreatic cancer [24]. Therefore, the 18.5% positivity among benign lesions in the present study is clinically plausible, particularly with biliary obstruction and pancreatic inflammation. Regarding emerging approaches, the systematic review by Kane et al. found a pooled AUC of 0.898 for multibiomarker panels compared with 0.803 for single biomarkers [9]. More recently, the study by Yablecovitch et al. achieved an AUC of 1.0 using MMP-7, syndecan-1, and CA 19-9 [25], while the study by Kawai et al. reported an AUC of 0.99, 90% sensitivity, and 98% specificity using miRNAs plus CA 19-9 [26]. In 2025, the study by Li et al. achieved 88.57% sensitivity and 91.67% specificity by combining imaging with EUS-FNA biomarkers [27]. Collectively, the present findings indicate that

serum CA 19-9 is a useful and accessible diagnostic adjunct in Bangladesh; however, clinical assessment, imaging, EUS-guided sampling, and histopathology remain necessary for definitive differentiation of benign and malignant pancreatic lesions.

LIMITATIONS

Because this was a single-center cross-sectional study with a relatively small sample, generalizability was limited. In addition, serum CA 19-9 may be influenced by biliary obstruction and benign inflammatory conditions, and histopathological confirmation was not available in every case.

CONCLUSION

Overall, serum CA 19-9 demonstrated good diagnostic utility in differentiating malignant from benign pancreatic lesions, with significantly higher levels observed in malignant cases. At a cut-off of >37 U/mL, CA 19-9 showed acceptable sensitivity, specificity, and overall diagnostic accuracy, while ROC analysis confirmed good discriminatory performance. However, false-positive elevations in benign conditions limit its use as a standalone test. Therefore, CA 19-9 should be interpreted alongside clinical findings, imaging, and histopathological or cytological evaluation for accurate diagnosis.

RECOMMENDATIONS

For clinical practice, serum CA 19-9 should be used as an adjunct rather than a standalone diagnostic test for pancreatic malignancy. Alongside CA 19-9, careful interpretation of clinical features, imaging findings, and histopathological or cytological confirmation is recommended, particularly in patients with biliary obstruction or inflammatory pancreatic disease. Further multicenter studies with larger samples should validate optimal cut-off values and improve diagnostic accuracy.

FUNDING

No funding sources

CONFLICT OF INTEREST

None declared

ETHICAL APPROVAL

The study was approved by the Institutional Ethics Committee.

REFERENCES

1. *Sung H, Filho AM, Laversanne M, Ferlay J, Siegel RL, Soerjomataram I, Jemal A, Bray F. Global cancer statistics 2024: GLOBOCAN estimates of incidence and mortality worldwide for 34 cancers in 186 countries. CA: A Cancer Journal for Clinicians. 2026 Jul;76(4):e70090.*
2. *Yu W, Zhou D, Meng F, Wang J, Wang B, Qiang J, Shen L, Wang M, Fang H. The global, regional burden of pancreatic cancer and its attributable risk factors from 1990 to 2021. BMC cancer. 2025 Jan 31;25(1):186.*
3. *Park W, Chawla A, O'Reilly EM. Pancreatic cancer: a review. Jama. 2021 Sep 7;326(9):851-62.*
4. *Rhee H, Park MS. The role of imaging in current treatment strategies for pancreatic adenocarcinoma. Korean Journal of Radiology. 2020 Aug 28;22(1):23.*
5. *Hossain MS, Saha PP, Jahan MU, Sharmin S, Afrin R, Yesmin L. Role of MDCT scan in the evaluation of pancreatic mass with histopathological correlation. Bangladesh Medical Research Council Bulletin. 2016;42(3):120-4.*
6. *Lee T, Teng TZ, Shelat VG. Carbohydrate antigen 19-9—Tumor marker: Past, present, and future. World journal of gastrointestinal surgery. 2020 Dec 27;12(12):468.*
7. *Xing H, Wang J, Wang Y, Tong M, Hu H, Huang C, Li D. Diagnostic value of CA 19-9 and carcinoembryonic antigen for pancreatic cancer: a meta-analysis. Gastroenterology research and practice. 2018;2018(1):8704751.*
8. *Boyd LN, Ali M, Leeflang MM, Treglia G, de Vries R, Le Large TY, Besselink MG, Giovannetti E, van Laarhoven HW, Kazemier G. Diagnostic accuracy and added value of blood-based protein biomarkers for pancreatic cancer: a meta-analysis of aggregate and individual participant data. EClinicalMedicine. 2023 Jan 1;55.*
9. *Kane LE, Mellotte GS, Mylod E, O'Brien RM, O'Connell F, Buckley CE, Arlow J, Nguyen K, Mockler D, Meade AD, Ryan BM. Diagnostic accuracy of blood-based biomarkers for pancreatic cancer: a systematic review and meta-analysis. Cancer research communications. 2022 Oct 20;2(10):1229-43.*
10. *Zhao B, Cheng Q, Cao H, Zhou X, Li T, Dong L, Wang W. Dynamic change of serum CA19–9 levels in benign and malignant patients with obstructive jaundice after biliary drainage and new correction formulas. BMC cancer. 2021 May 7;21(1):517.*
11. *Liu C, Deng S, Jin K, Gong Y, Cheng H, Fan Z, Qian Y, Huang Q, Ni Q, Luo G, Yu X. Lewis antigen-negative pancreatic cancer: An aggressive subgroup. International journal of oncology. 2020 Feb 17;56(4):900-8.*
12. *Yang J, Xu R, Wang C, Qiu J, Ren B, You L. Early screening and diagnosis strategies of pancreatic cancer: a comprehensive review. Cancer Communications. 2021 Dec;41(12):1257-74.*
13. *Jahan SS, Hussain MM, Islam MT, Dewan MN, Das PK, Alam SI. Clinical Value of Serum Ca 19.9 Level as a Tumor Marker in Pancreatic Malignancy. Journal of Dhaka Medical College. 2024;33(1):3-6.*
14. *Grassia R, Imperatore N, Capone P, Cereatti F, Forti E, Antonini F, Tanzi GP, Martinotti M, Buffoli F, Mutignani M, Macarri G. EUS-guided tissue acquisition in chronic pancreatitis: Differential diagnosis between pancreatic cancer and pseudotumoral masses using EUS-FNA or core biopsy. Endoscopic Ultrasound. 2020 Apr 15;9(2):122.*
15. *Zhao B, Zhao B, Chen F. Diagnostic value of serum carbohydrate antigen 19-9 in pancreatic cancer: a systematic review and meta-analysis. European journal of gastroenterology & hepatology. 2022 Sep 1;34(9):891-904.*
16. *Yang Y, Yan S, Tian H, Bao Y. Macrophage inhibitory cytokine-1 versus carbohydrate antigen 19–9 as a biomarker for diagnosis of pancreatic cancer: A PRISMA-compliant meta-analysis of diagnostic accuracy studies. Medicine. 2018 Mar 2;97(9):e9994.*
17. *Skulimowski A, Durczyński A, Strzelczyk J, Hogendorf P. Comparison of clinical usefulness of serum Ca125 and CA19-9 in pancreatic adenocarcinoma diagnosis: meta-analysis and systematic review of literature. Biomarkers. 2021 May 19;26(4):287-95.*
18. *Cao S, Hu Y, Gao X, Liao Q, Zhao Y. Serum carbohydrate antigen 19-9 in differential diagnosis of benign and malignant pancreatic cystic neoplasms: a meta-analysis. PLoS One. 2016 Nov 11;11(11):e0166406.*
19. *Okasha H, Behiry ME, Ramadan N, Ezzat R, Yamany A, El-Kholi S, Ahmed G. Endoscopic ultrasound-guided fine needle aspiration in diagnosis of cystic pancreatic lesions. Arab Journal of Gastroenterology. 2019 Jun 1;20(2):86-90.*
20. *Fahrmann JF, Schmidt CM, Mao X, Irajizad E, Loftus M, Zhang J, Patel N, Vykoukal J, Dennison JB, Long JP, Do KA. Lead-time trajectory of CA19-9 as an anchor marker for pancreatic cancer early detection. Gastroenterology. 2021 Mar 1;160(4):1373-83.*
21. *Mayerle J, Kalthoff H, Reszka R, Kamlage B, Peter E, Schniewind B, González Maldonado S, Pilarsky C, Heidecke CD, Schatz P, Distler M. Metabolic biomarker signature to differentiate pancreatic ductal adenocarcinoma from chronic pancreatitis. Gut. 2018 Jan;67(1):128-37.*
22. *Zhang J, Wang Y, Zhao T, Li Y, Tian L, Zhao J, Zhang J. Evaluation of serum MUC5AC in combination with CA19-9 for the diagnosis of pancreatic cancer. World journal of surgical oncology. 2020 Feb 7;18(1):31.*
23. *Karamya ZA, Kovács A, Illés D, Czakó B, Fazekas A, Farkas N, Hegyi P, Czakó L. Prevalence of autoimmune pancreatitis in pancreatic resection for suspected malignancy: a systematic review and meta-analysis. BMC gastroenterology. 2024 Aug 21;24(1):278.*
24. *Yan T, Ke Y, Chen Y, Xu C, Yu C, Li Y. Serological characteristics of autoimmune pancreatitis and its differential diagnosis from pancreatic cancer by using a combination of carbohydrate antigen 19-9, globulin, eosinophils and hemoglobin. PloS one. 2017 Apr*

3;12(4):e0174735.

25. *Yablecovitch D, Nadler M, Ben-Horin S, Picard O, Yavzori M, Fudim E, Duchan MT, Sakhnini E, Lang A, Lahav M, Saker T. Serum matrix metalloproteinase-7, Syndecan-1, and CA 19-9 as a biomarker panel for diagnosis of pancreatic ductal adenocarcinoma. Cancer Medicine. 2024 Sep;13(17):e70144.*
26. *Kawai M, Fukuda A, Otomo R, Obata S, Minaga K, Asada M, Umemura A, Uenoyama Y, Hieda N, Morita T, Minami R. Early detection of pancreatic cancer by comprehensive serum miRNA sequencing with automated machine learning: Clinical Studies. British Journal of Cancer. 2024 Oct 19;131(7):1158-68.*
27. *Li CF, Hao LX, Chen YJ, Lin ED, Zhang CP, Wu LH, Liao XY, Zhou JL, Zhu JH, Zhan LH, Liang XM. A Novel Diagnostic Model of Biomarkers in the Washing Fluid Obtained by EUS-FNA in Pancreatic Cancer. Journal of gastrointestinal cancer. 2025 Dec;56(1):89.*